

TRABECULECTOMY SURGERY DECISION MAKING AND TECHNIQUE

Marcos Reyes, MD; James A. Fox, MD;
and Mahmoud A. Khairi, MD

The goal of glaucoma filtration surgery is to decrease the intraocular pressure (IOP) to a level that will arrest or retard the loss of the nerve fiber layer. The unifying feature of all glaucoma filtering surgery is to create a drainage system that flows into a newly created sub-Tenon's/conjunctival reservoir, the "bleb." The creation of a bleb allows the aqueous to bypass the nonfunctioning or, more commonly, poorly functioning trabecular meshwork and thereby lower the IOP.

PREOPERATIVE ASSESSMENT

Typically, the surgical option becomes a viable management alternative in the presence of advancing visual field defects and/or progressive loss of retinal nerve fiber layer, despite maximal tolerated medical therapy and laser trabeculoplasty (when appropriate).

Risk factors for surgical failure and the quality of postoperative care should be considered prior to filtration surgery. The risk factors for filtration failure^{1,2} include young patients (except for young myopes <50 years old, who are at risk for overfiltration and hypotony maculopathy), diabetes, higher preoperative IOP, African American patients, iris/angle neovascularization, uveitis, and prior failed filtration surgery. The patient and/or caretakers must understand that the postoperative care is just as important as the surgery itself and that all postoperative instructions must be followed. Poor postoperative compliance can lead to prolonged uveitis, posterior synechia, cystoid macular edema, and bleb failure.

Ch. 4 - TRAB TECHNIQUE
Ch. 8 - TUBE TECHNIQUE
Ch. 39 - EXPRESS

Additional Perioperative Considerations

Hyperopic Eyes

1. Prone to shallow/flat anterior chambers postoperatively. Consider tighter scleral flap closure to avoid postoperative hypotony and shallow/flat anterior chamber.
2. When associated with chronic angle closure, there is an increased risk of malignant glaucoma.

Pseudophakic (Postoperative) Eyes

1. Check conjunctival mobility prior to choosing a filter site as prior cataract surgery might lead to conjunctival scarring if performed through a scleral tunnel.
2. Use caution when creating a scleral flap through an old cataract wound incision because there is a risk of scleral flap avulsion.
3. Perform anterior vitrectomy for vitreous in the anterior chamber.

PERIOPERATIVE SYSTEMIC MEDICATIONS

Oral steroids may be useful in patients with uveitic glaucoma but should only be used in selected cases and preferably after consultation with an internist or uveitis specialist. Intraocular inflammation at the time of surgery is highly associated with bleb failure.

If possible, both anticoagulants and antiplatelet agents should be stopped to decrease the risk of intraoperative, retrobulbar, or suprachoroidal hemorrhage. Cessation of blood thinners should be done only after consultation with the patient's internist or cardiologist.³ Many surgeons choose not to discontinue these medications due to the elevated risk of vascular events. This issue should be discussed thoroughly with the patient.

BASIC SURGICAL TECHNIQUE

Glaucoma filtration surgery is performed in either the superonasal quadrant or directly superior, leaving the superotemporal quadrant available for a repeat filtration surgery or the use of a glaucoma drainage device. Anesthesia is typically accomplished effectively with a retrobulbar block consisting of a combination of lidocaine, bupivacaine, and hyaluronidase. Lid blocks and general anesthesia are rarely required.

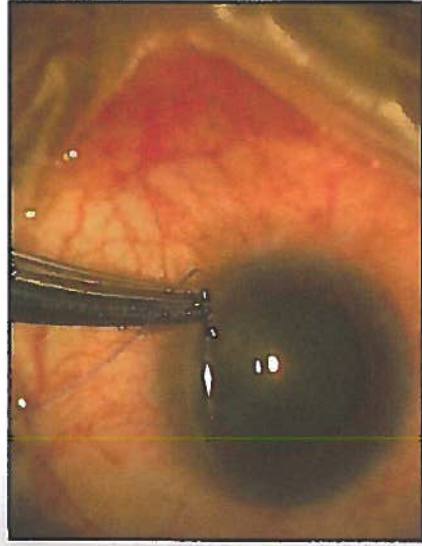


Figure 4-1. Superior corneal bridle suture.

Traction Sutures

A superior corneal bridle suture is the common approach used to rotate the eye inferiorly (Figure 4-1). This is performed with a 6-0 or 7-0 Vicryl or silk suture on a spatulated needle passed through clear, midstromal cornea approximately 1 mm from the superior limbus for approximately 2 to 2.5 mm. Gentle traction on the suture assures its integrity prior to taping or clamping the suture to the inferior drape or handing it over to an assistant to hold. An alternative approach is to place an inferior corneal bridle suture.

Avoid passing the needle into the anterior chamber, which produces a persistent aqueous leak at the suture site that could subsequently lead to intraoperative hypotony, a shallow anterior chamber, and possibly prevent the use of mitomycin C (MMC) due to the risk of intraocular tracking.

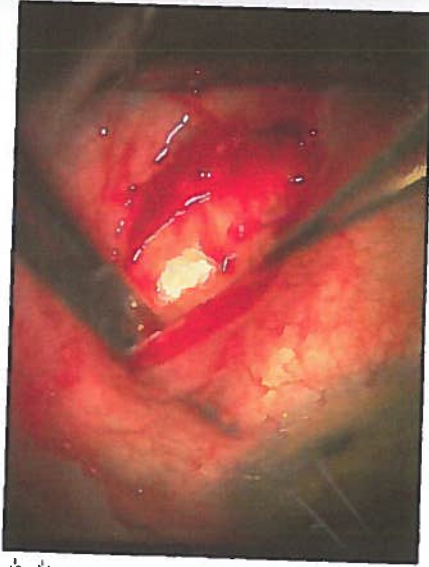Creation of the Conjunctival Flap

The conjunctival flap may be either limbus- or fornix-based. Evidence suggests that both are successful.⁴ However, debate continues regarding which is more efficacious. With either technique, the conjunctival tissue will ultimately function as a fluid flow resistor. It is therefore important to avoid excessive tissue manipulation, which can cause subconjunctival fibrosis, the most common cause of filtration failure. Only nontoothed forceps should be used on this tissue.

Limbus-Based Flap

Limbus-based conjunctival flaps are less likely to leak postoperatively, reducing their likelihood of flattening or scarring down.

Figure 4-2. Blunt dissection of the conjunctival-Tenon's flap.



It is necessary to make the initial conjunctival incision parallel to the eyelid margin, a minimum of 8 mm posteriorly. The Tenon's fascia, in turn, is grasped and incised until the episclera is visualized. The conjunctival-Tenon's wound should be lengthened to approximately 2 clock hours. The conjunctiva and Tenon's tissue should only be incised when in the grasp of forceps and while they are raised over the episclera to avoid incorporating a rectus muscle with these tissues.

The conjunctival-Tenon's flap is bluntly dissected to the limbus through the insertion of Tenon's fascia (approximately 0.5 to 0.75 mm posterior to the limbus) to the insertion of the conjunctiva, which is approximately 0.5 mm onto clear cornea (Figure 4-2). Meticulous hemostasis using tapered tip cautery is then performed.

Fornix-Based Flap

Fornix-based conjunctival flaps have the advantage that they are easier to perform and can be used as an alternative to the limbal-based flap (Figure 4-3). These are initiated with a 1.5 to 2 clock-hour limbal peritomy and blunt dissection, which is carried posteriorly using blunt-tipped Westcott scissors through the insertion of Tenon's fascia. Blunt dissection is then carried posteriorly and laterally as far as the Westcott scissors can reach to obtain the most diffuse bleb possible.

Creating a Scleral Flap

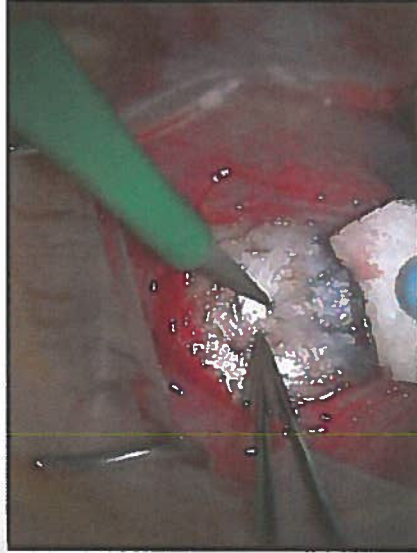
The scleral flap, if adequately sutured, is a temporary resistor to the flow of aqueous through the sclerotomy site in the early postoperative period, reducing the incidence of hypotony. The shape of the scleral flap is of little consequence as long as the flap completely covers the sclerectomy. Our preference is to make a triangular flap 3.5 mm × 3.5 mm × 3.5 mm with

**SQUARE FLAP IS ALSO COMMON
TYPICALLY ~ 2 MM x 2 MM END FE PAPER**

Figure 4-3. Limbal peritomy to create a fornix-based conjunctival flap.

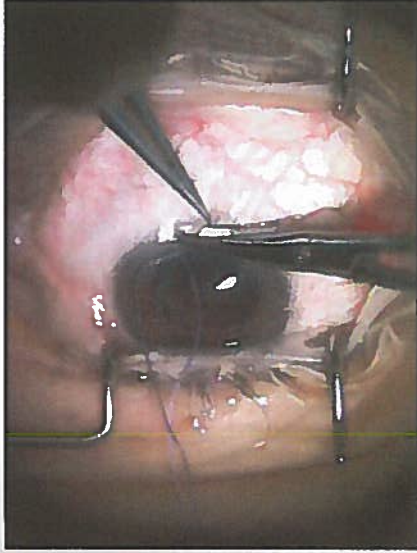

Figure 4-4. Creating a triangular-shaped scleral flap with a 15-degree blade.



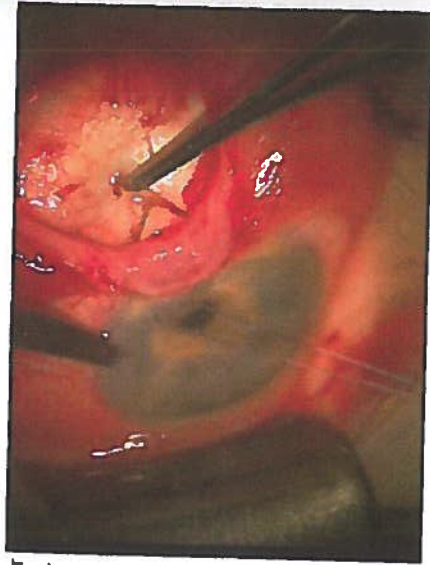
a 15-degree blade, with a flap thickness of one-half to two-thirds sclera thickness (to avoid flap avulsion) (Figure 4-4). The flap is dissected anteriorly, beyond the gray line and into clear cornea anterior to the sclera spur and ciliary body, into clear cornea in a lamellar fashion with the same blade.

Mitomycin C

MMC is an antifibrotic agent used intraoperatively to reduce postoperative subconjunctival scarring, thus reducing the need for or eliminating multiple postoperative subconjunctival injections of 5-fluorouracil (5-FU), which historically was the antifibrotic agent used routinely prior to the widespread usage of MMC. When compared to 5-FU, MMC produces less corneal toxicity.⁵ However, a dose-dependent complication associated with MMC

Figure 4-5. Anterior chamber paracentesis.

ALTERNATIVE:
 0.5MG/ML - 2 MG/ML
 DIVIDED IN 2% LIDO
 EPI - INJECTED
 SUBCONS BEFORE
 PERITOMY
 CURRENTLY FAVORED
 BY JSS/KVM/IPC/
 EA.



administration is long-term postoperative hypotony with associated maculopathy,⁶ most commonly due to an avascular thin-walled bleb that over-filtrates. However, aqueous hypo-secretion secondary to ciliary body toxicity may play a role in some cases.⁷

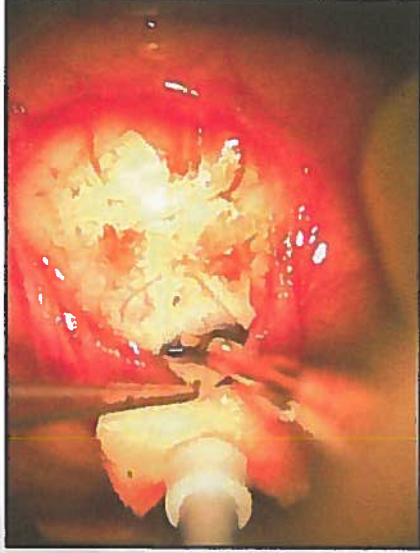
The concentration of MMC (0.2 to 0.5 mg/mL) used and the duration (2 to 5 minutes) of application during glaucoma filtration surgery varies in the literature.⁸⁻¹⁰ To reduce the risk of long-term hypotony with maculopathy, the duration of MMC exposure should be adjusted according to the risk factors of the individual patient.

Because MMC can be highly toxic to the corneal endothelium and tissues of the anterior segment,^{11,12} it should be applied in a controlled manner to bare sclera prior to entering the eye. A cellulose or cut end of a Weck-Cel sponge saturated with MMC is applied to bare sclera. We recommend diffuse application of multiple MMC sponges, under all areas of Tenon's fascia, to decrease the incidence of high avascular localized blebs and to promote low diffuse filtering blebs. After the exposure period, the sponge is removed and the surgical site is thoroughly irrigated with a full container (15 mL) of balanced salt solution.

Paracentesis

Placement of a temporal-beveled, self-sealing paracentesis during filtration surgery before the sclerotomy but after application/rinsing of an antifibrotic agent is essential in allowing the surgeon access to the anterior chamber, similar to cataract surgery (Figure 4-5). A paracentesis enables the surgeon to allow for gradual pressure decline in patients in whom the IOP is high (reducing the risk of suprachoroidal hemorrhage), and to reform the anterior chamber to assess for adequate filtration at the flap margins after sclera flat closure.

Figure 4-6. Creating a sclerotomy with a Kelly-Desemet punch.



Sclerectomy

There are 2 common methods for making the sclerotomy opening. For both methods, the anterior chamber is entered at the anterior most point of the scleral bed adjacent to the scleral flap with a 15-degree blade, or other such sharp knife. For the first method, 2 radial incisions centered under the scleral flap are made approximately 1.5 to 2 mm apart with Vannas scissors. The block is retracted posteriorly and excised with Vannas scissors. Alternatively, a sclerectomy can be made with a Kelly-Desemet punch (our preferred method). Two to 3 punches may be required to make a sclerotomy of adequate size (Figure 4-6). If the iris balloons forward through the surgical opening at any time during the construction of the sclerectomy, a small radial snip of the iris with Vannas scissors can deflate the ballooning. → PREFER IRIS PROLAPSE - CAN GRASP IRIS WITH FORCEPS AND EXCISE TO CREATE

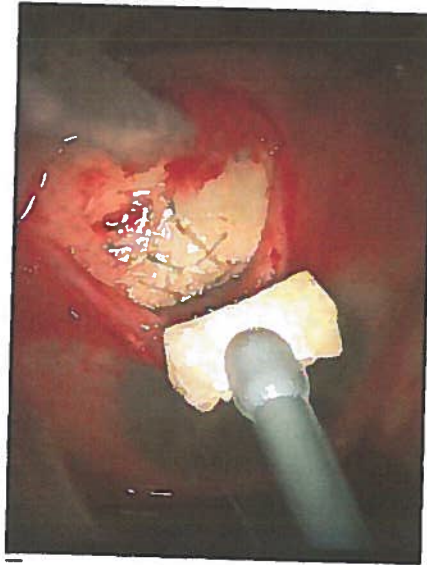
Iridectomy

A peripheral iridectomy is performed to prevent obstruction/incarceration of the iris in the sclerotomy. The ideal iridectomy should be larger than the sclerotomy in all dimensions (wide at its base but short vertically) to avoid iatrogenic polycoria and its associated monocular diplopia). With the scleral flap lifted, the iris is grasped 0.5 mm from the iris root and retracted through the sclerotomy. The scissors are opened enough to encompass the retracted iris, and then in one smooth cut, the iridectomy is made (Figure 4-7). The iris is repositioned with a stream of balanced salt solution or by closing and gently massaging over the scleral flap. Upon completion of the iridectomy, the surgeon should have a view of the ciliary processes and occasionally the lens equator. If iris remnants or ciliary processes occlude the sclerectomy,

Figure 4-7. Surgical iridectomy.

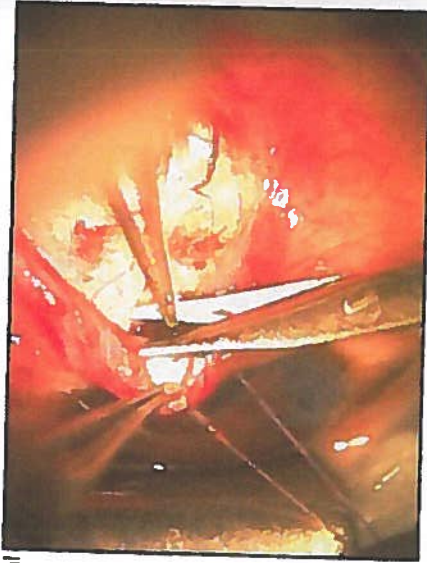

Figure 4-8. Scleral flap sutures.

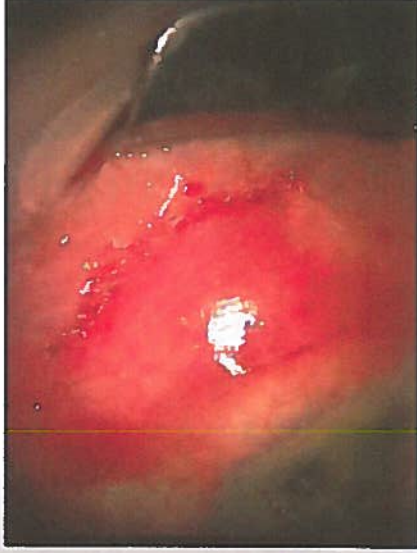

these should be excised only with great caution because it is exceedingly easy to damage the lens or hyaloid face.

Scleral Flap Closure

The scleral flap should be closed tightly enough to prevent postoperative hypotony. The flap is closed with interrupted 10-0 nylon sutures. A 3-1-1 knot buries well and secures the flap adequately. Usually 3 to 5 sutures are used to adequately close the flap (Figure 4-8). After the flap is secured, the anterior chamber is reformed through the paracentesis with balanced salt solution, and the filtration is checked at the flap margins with a Weck-Cel sponge. If the IOP and anterior chamber depth are

Figure 4-9. Limbal-based flap closure.



maintained with slow oozing of aqueous humor, then the scleral flap closure is usually adequate. However, if aqueous humor flows freely and the anterior chamber shallows, additional sutures are required. Conversely, if aqueous humor does not flow, loosen, remove, or replace sutures. Also, it may be necessary to reopen the scleral flap and inspect the sclerectomy to ensure it is not obstructed.

Conjunctival Closure

Watertight conjunctival closure using nontoothed forceps is necessary to create an elevated filtering bleb. Tissues should be brought to apposition only, as tight sutures "cheese-wire" postoperatively, creating a leaky, inflamed wound. Meticulous closure of the conjunctiva can save many postoperative hours dealing with the complications related to poorly closed wounds.

Limbus-Based Flap Closure

While the terminology is confusing, a limbus-based flap is performed with a conjunctival and Tenon's incision, typically performed in the superior fornix, approximately 8 to 10 mm posterior to the limbus. Most surgeons favor the use of running conjunctival closures with 8-0 or 9-0 absorbable suture (eg, Vicryl) on a BV needle, beginning on the side of the surgeon's dominant hand. The running suture closes the Tenon's fascia first, followed by the conjunctiva (Figure 4-9). Weck-Cel sponges are then used to assure the wound's watertight closure. It is useful to lock the running suture every second to third throw to provide watertight closure. Care should be taken not to take large bites of the anterior Tenon's fascia or conjunctiva, as this

may cause the wound to migrate anteriorly, creating unwanted tension on the limbal conjunctiva.

Fornix-Based Flap Closure

While the terminology is confusing here as well, a fornix-based flap is created by incising the conjunctiva directly at the limbus, and dissecting posteriorly beneath Tenon's. Fornix-based flaps should be closed in a watertight manner as well. Closure with winged sutures using nylon or Vicryl at either end of the conjunctival flap positions the leading edge of the flap over the limbus. Alternatively, if this closure is inadequate, 3 to 4 long mattress sutures are placed at the limbus using 10-0 nylon or 8-0 to 10-0 Vicryl on a spatulated needle. The suture should be placed through midstromal cornea. Exposed nonabsorbable sutures are removed after wound healing has occurred.

Seidel testing for bleb leaks with a saturated fluorescein strip should be performed at the conclusion of fornix-based surgery. If a bleb leak is detected, it should be closed with a single suture or a horizontal mattress suture and the wound rechecked with fluorescein.

INTRAOPERATIVE COMPLICATIONS

Buttonholes

Buttonholes can generally be avoided by meticulous handling of the conjunctiva with nontoothed forceps. If a large buttonhole overlying the filter site is found early in the surgery, the surgeon should consider relocating the filter to the adjacent quadrant. If the buttonhole is found or created late in the surgery, take care to not extend it while completing the surgery. Then make the repair with a tapered 9-0 or 10-0 Vicryl or nylon suture on a tapered needle in a mattress fashion, taking care to incorporate Tenon's tissue in your needle passes for stability, if possible.

Flap Dehiscence

A thin scleral flap is at risk for avulsion from the eye during the surgery. If done before making the sclerotomy, it is recommended to abandon that site and begin again in an adjacent area. If done after the sclerotomy, it is recommended that a scleral patch graft be placed over the sclerotomy and closed in watertight fashion, abandoning the filtration.

Bleeding

Bleeding from the sclerotomy edges and the iridectomy edges is not uncommon. Gentle cautery of small bleeders can be performed under

direct visualization with taper tip cautery. To stop persistent bleeding, epinephrine 1:100,000 solution (sterile and unpreserved) can also be used. Take care to not inadvertently enlarge the sclerotomy site, as this can cause overfiltration. In addition, cautery of the iris should be performed with caution so as to not break the anterior hyaloid face and encounter vitreous or to violate the lens capsule in a phakic patient.

SUBCONJUNCTIVAL INJECTIONS

At the conclusion of filtering surgery, subconjunctival dexamethasone phosphate 5mg is injected opposite the site of the filtering bleb. Injec antibiotics can be used, but some surgeons feel it may increase postoperative inflammation. Cycloplegics (eg, atropine 1%, homatropine 5%, or scopolamine 0.25%) may be given at the conclusion of the surgery if the patient is still phakic or has a shallow chamber to begin with. This is followed by a combination steroid/antibiotic ointment (eg, Tobradex or Maxitrol), which is then applied. The eye is then gently patched and an eye shield is applied.

POSTOPERATIVE MANAGEMENT

Topical steroids improve intermediate and long-term postoperative IOP control after filtering surgery by decreasing postoperative inflammation and scarring. Prednisolone acetate 1% is administered every 1 to 2 hours initially and tapered over 8 to 12 weeks, depending on the patient's response. No additional benefit has been demonstrated with the use of systemic prednisone.¹³ Cycloplegics (eg, scopolamine 0.25%) can be used twice a day for 2 to 3 weeks after surgery to help maintain anterior chamber depth and prevent synechia. Antibiotics are given over a 2-week period. In addition, an antibiotic/steroid ointment is generally given at bedtime to aid in antibiotic and anti-inflammatory coverage while asleep.

It is important to understand that postoperatively there could be changes in the medical regimen that may affect the IOP in the fellow eye due to steroid response,¹⁴ discontinuation of oral glaucoma medication, and confusion with medications. If the IOP reaches unsafe levels in the fellow eye, the surgeon must advance therapy accordingly.

Postoperative Scleral Flap Suture Release

If the IOP is not adequately lowered, laser suture lysis is a technique that allows the surgeon to modify scleral flap aqueous humor outflow resistance postoperatively.¹⁵ With this available, the scleral flap can be closed more tightly intraoperatively, thus reducing the occurrence of postoperative hypotony and its attendant complications without as much concern for postoperative elevated IOP.

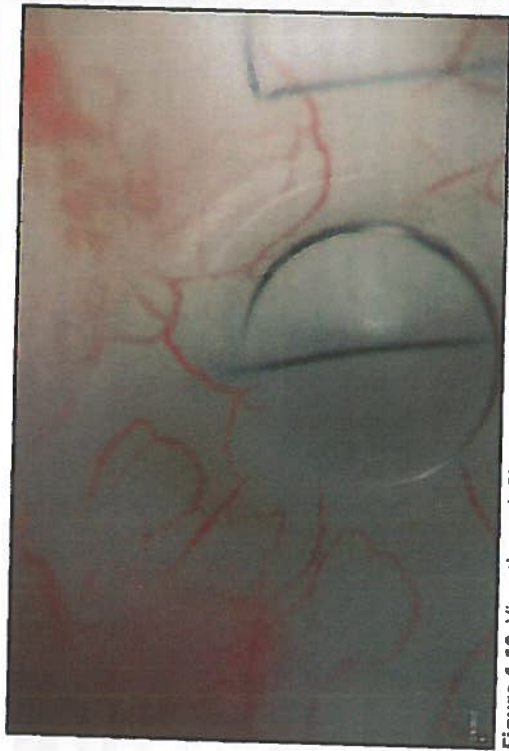


Figure 4-10. View through Blumenthal laser suture lysis lens.

CAN PERFORM LSL EARLIER, BUT HIGHER RISK FOR LEAK OR SCH!

Suture lysis is performed sequentially; that is, 1 suture at a time. The time interval between cutting sutures can be from hours to days, depending on the response. Suture lysis can be performed as early as 1 week after filtering surgery and as far out as 18 weeks after surgery.¹⁶

After application of topical anesthesia, a Zeiss, Hoskins, or Blumenthal lens is used to flatten the bleb overlying the scleral flap. The lens may need to be held in place for a short period of time (usually under a minute) to compress the bleb tissues and improve the view of the suture before laser application (Figure 4-10). An argon red or green wavelength is used with settings of 240 to 400 mW, 0.1 seconds, and a 50 μ m spot size (see Appendix E for alternative laser settings). Argon red is useful if subconjunctival hemorrhage or pigmentation is present due to its reduced absorption by these substances. The suture should clearly separate when successfully cut. If there is no clear separation of the suture, it was not cut or it was not functionally closing the scleral flap. Additional sutures may need to be cut in the latter situation. Occasionally, a cut end stands vertically inside the bleb after lysis. This can be avoided if the suture is cut at its 2 ends. Releasable sutures, a method to remove scleral flap sutures at the slit lamp (beyond the scope of this chapter), can be used to circumvent the need for a laser.

After lysing or pulling a suture, it is important to judge the patency of the flap by using digital pressure (through the superior lid) or the Carlo Traverso maneuver (pressure using a cotton applicator adjacent to but outside the flap boundary)¹⁷ to determine whether there is an elevation in the bleb after suture lysis.

THE FAILED FILTER

Unfortunately, even surgery performed and followed in the most meticulous manner may fail. Failure occurs when aqueous humor meets elevated resistance between the sclerectomy and the conjunctival epithelium.

Signs of bleb failure include the following:

1. Increased bleb vascularity.
2. Increased bleb wall thickness.
3. Decreased elevation of the bleb.
4. Reduction in conjunctival microcysts.
5. Increased IOP.

Causes of bleb failure include the following:

1. Subconjunctival (episcleral) fibrosis (most common cause).
2. Scleral flap fibrosis
3. "Tenon's cyst" formation (a fluid-filled cavity lined internally by fibrous tissue preventing filtration).
4. Obstruction of the sclerectomy by iris, vitreous or lens (as seen by gonioscopy).

Therapeutic options include the following:

1. Postoperative topical anti-inflammatory drop adherence, early digital massage, and 5-FU injections (for causes 1 and 2 prior to formation).
2. External bleb needle revision (for causes 1, 2, and 3).
3. Nd:YAG or argon laser reopening of the sclerectomy (for cause 4).

Digital Massage

Digital massage is used to push aqueous through the filter site in an attempt to prevent or slow the fibrosis that causes filtration surgery to ultimately fail.

While the patient is looking up and nasally, the index finger is used to identify the infraorbital rim. The patient should then place pressure on the globe through the lower lid with pressure directed inward and upward for 10 seconds with the soft fingerprint portion of the index finger. This is repeated 1 to 2 times per day until the patient is seen in clinic to reassess the filtering site. Risk is involved with this maneuver, and specific instructions and cautions must be given to ensure that the patient does not cause injury to him or herself. For this reason, many physicians choose not to use this maneuver.

Bleb Needle Revision

In cases of bleb failure resulting from an elevated thick-walled encapsulated bleb (Tenon's cyst) or from advanced episcleral fibrosis causing a flat bleb, a needling procedure¹⁸ may be used in an attempt to successfully revise the original filtering surgery. This is performed using a TB syringe to draw up 0.1 mL of sterile nonpreserved 1% lidocaine and 0.1 mL of 0.4 mg/mL MMC, yielding a final concentration of 0.2 mg/mL of MMC. Under sterile technique in the operating room or at the slit lamp, the diluted MMC is injected subconjunctivally in the superotemporal quadrant, far from the failed bleb (in the case of a superonasal bleb). If at the slit lamp, massage the MMC through the closed eyelid, toward the site of the initial surgery, until the area is flat. If in the operating room, you may use a cotton tip applicator on the conjunctiva to accomplish this flattening. A 25- or 27-gauge needle on a TB syringe or a 1.0 mm side-port blade is then inserted subconjunctivally, far from the bleb and away from the area of the MMC, and advanced until reaching the failed bleb. The sharp edges are then used to break up scar tissue, lift the flap, and enter the anterior chamber through the sclerotomy site to reinstate aqueous flow. Success is accomplished when the bleb reforms or becomes more diffuse after injecting balanced salt solution into the anterior chamber through a previously formed paracentesis. The conjunctival entry sites may be closed with suture or hand-held cautery.

ISS/IPC
TYPICALLY
USE MUCH
LESS MMC
USUALLY
0.01-0.02
ML MMC
IN 0.1ML
LIDOCAINE

CONCLUSION

Elevated IOP control via trabeculectomy is sometimes required to control glaucoma. Risk assessment, perioperative observation and management, and selection of the proper intraoperative technique are crucial to ensuring the success of the procedure. Gaining a comprehensive understanding of the theories underlying the various approaches and techniques of this classic filtration procedure will prepare the reader to learn glaucoma surgery. Additional pearls to more effective glaucoma surgery can be gleaned from Table 4-1.

TABLE 4-1. FILTRATION SURGERY KEY PEARLS

Short conjunctival flap (limbus-based flap)	Reduces potential filtration area and increases likelihood of postoperative failure. Initiate conjunctival flap at least 8 mm from the limbus.
Toothed forceps for conjunctival manipulation	Use of nontoothed forceps and gentle handling of tissues reduces buttonholes and postoperative inflammation.
Thin or small scleral flap	The scleral flap should be at least half the total scleral thickness and large enough to functionally cover the sclerotomy site to prevent prolonged postoperative hypotony.
Paracentesis too small, cannot be found or cannot be cannulated	To cannulate easily, a paracentesis must have a large internal (endothelial) opening and known location and orientation (test paracentesis before continuing case).
Iridectomy imperforate or too small	The iridectomy must be patent and extend to the posterior sclerectomy margins (so one can see the red reflex or ciliary processes). Extreme caution must be used to enlarge a small iridectomy to avoid vitreous loss.
Sclerectomy site too far posteriorly	Excessive bleeding or occlusion of the sclerectomy by the ciliary body can be avoided by making the initial anterior chamber entry site as far anterior as possible (well into the limbal gray-blue zone).
Sclerectomy site too close to lateral scleral flap margin	The scleral flap must completely cover the sclerectomy, otherwise resistance to aqueous flow will be low and hypotony will result.
Occlusion of the sclerectomy by ciliary processes	Particularly seen in small hyperopic eyes. An anterior sclerectomy site is helpful. Ciliary processes can be gently cauterized, grasped with 0.12 forceps and excised with Vannas scissors if necessary.
Vitreous loss through sclerectomy site	Fortunately a rare complication. A meticulous Weck-Cel vitrectomy can salvage the bleb. Postoperative hypotony with a shallow anterior chamber must be avoided (to prevent posterior vitreous from entering the sclerectomy site).
Scleral flap closure (too tight or too loose)	With irrigation through the paracentesis, fluid should flow slowly with a maintained anterior chamber depth.
Conjunctival wound leak	Wound leaks can be reduced by meticulous wound closure and testing with fluorescein.

REFERENCES

1. AGIS Investigators. The Advanced Glaucoma Intervention Study (AGIS): 11. Risk factors for failure of trabeculectomy and argon laser trabeculectomy. *Am J Ophthalmol*. 2002;134(4):481-498.
2. Phillips B, Krupin T. The risk profile of glaucoma filtration surgery. *Curr Opin Ophthalmol*. 1999;10(2):112-116.
3. Law SK, Song BJ, Yu F, Kurbanyan K, Yang TA, Caprioli J. Hemorrhagic complications from glaucoma surgery in patients on anticoagulation therapy or antiplatelet therapy. *Am J Ophthalmol*. 2008;145(4):736-746.
4. Kohl DA, Walton DS. Limbus-based versus fornix-based conjunctival flaps in trabeculectomy: 2005 update. *Int Ophthalmol Clin*. 2005;45(4):107-113.
5. Skuta GL, Beeson CC, Higginbotham EJ, et al. Intraoperative mitomycin versus postoperative 5-fluorouracil in high-risk glaucoma filtering surgery. *Ophthalmology*. 1992;99:438-444.
6. Shields MB, Scroggs MW, Sloop CM, et al. Clinical and histopathologic observations concerning hypotony after trabeculectomy with adjunctive mitomycin C. *Am J Ophthalmol*. 1993;116:673-683.
7. Rockwood EJ, Parrish RK II, Heuer DK, et al. Glaucoma filtering surgery with 5-fluorouracil. *Ophthalmology*. 1987;94:1071-1078.
8. Kitazawa Y, Suemori-Matsushita H, Yamamoto T, et al. Low-dose and high-dose mitomycin trabeculectomy as an initial surgery in primary open-angle glaucoma. *Ophthalmology*. 1993;100:1624-1628.
9. Neelakantan A, Rao BS, Vijaya L, et al. Effect of the concentration and duration of application of mitomycin C in trabeculectomy. *Ophthalmic Surg*. 1994;25:612-615.
10. Megevan GS, Salmon JF, Scholtz RP, Murray AD. The effect of reducing the exposure time of mitomycin C in glaucoma filtering surgery. *Ophthalmology*. 1995;102:84-90.
11. Derick RJ, Pasquale L, Quigley HA, Jampel H. Potential toxicity of mitomycin C. *Arch Ophthalmol*. 1991;109:1635.
12. Seah SK, Prata JA Jr, Minckler DS, et al. Mitomycin-C concentration in human aqueous humor following trabeculectomy. *Eye*. 1993;7:652-655.
13. Starita RJ, Fellman RL, Spaeth GL, et al. Short and long-term effects of postoperative corticosteroids on trabeculectomy. *Ophthalmology*. 1985;92:938-946.
14. Schwartz B. The response of ocular pressure to corticosteroids. *Int Ophthalmol Clin*. 1966;6(4):929-989.
15. Savage JA, Simmons RJ. Staged glaucoma filtration surgery with planned early conversion from scleral flap to full-thickness operation using the argon laser. *Ophthalmic Laser Therapy*. 1986;1:201.
16. Pappa KS, Derick RJ, Weber PA, et al. Late argon laser suture lysis after mitomycin C trabeculectomy. *Ophthalmology*. 1993;100(8):1268-1271.
17. Spaeth GL. *Ophthalmic Surgery: Principles and Practice*. Philadelphia, PA: Saunders; 2003.
18. Shetty RK, Wartluft L, Moster MR. Slit-lamp needle revision of failed filtering blebs using high-dose mitomycin C. *J Glaucoma*. 2005;14(1):52-56.

5

TRABECULECTOMY MANAGEMENT OF POSTOPERATIVE COMPLICATIONS

Jonathan A. Eisengart, MD

By its nature, trabeculectomy typically entails much more risk than cataract surgery. However, thoughtful and successful management of postoperative complications can significantly reduce the risk of long-term harm to the patient.

HYPOTONY

Assessment

Hypotony is one of the most dreaded complications of trabeculectomy and is one of the major causes of permanent reduction in visual acuity after glaucoma surgery. Hypotony itself, however, does not cause vision loss. Rather, the complications of hypotony, such as maculopathy, flat anterior chambers, and choroidal hemorrhages, can cause vision loss. The decision whether to intervene medically or surgically to reverse hypotony is dictated by the risk of vision loss. For example, a patient with an intraocular pressure (IOP) chronically in the range of 2 to 4 mm Hg can be safely observed if the anterior chamber is deep and the posterior segment examination is normal. Conversely, a flat anterior chamber with lens–cornea touch needs immediate intervention to prevent deceleration of the cornea. Hypotony maculopathy deserves definitive surgical treatment within several weeks to prevent permanent retinal damage (although significant recovery of vision can occur even after several years).¹

Treatment for hypotony is directed at the underlying cause. In most cases, hypotony in the early postoperative period is due to overfiltration. Overfiltration is recognized by hypotony in the setting of a large and/or diffuse bleb and relatively quiet eye. A bleb leak can also contribute to

Complications of Hypotony

- Shallow anterior chamber
 - Mild to moderate shallowing
 - Iris–cornea touch
 - Lens–cornea touch
- Choroidal effusion/ciliary body detachment
- Choroidal hemorrhage
- Hypotony maculopathy
- Cystoid macular edema

hypotony, and needs to be ruled out with a Seidel test. More rarely, hypotony may be caused by aqueous hyposecretion, either from marked postoperative inflammation, uveitis, or ocular ischemia. Hyposecretion associated with inflammation is best treated with cycloplegia and frequent topical, and possibly systemic, steroids.

Medical Management

Most cases of postoperative hypotony, however, are due to overfiltration and typically respond to a reduction of topical steroids. This will allow for additional scarring and a natural rise in IOP over days to weeks. A cycloplegic is often added, which can be especially helpful in anterior chamber shallowing. In some patients, it might be prudent to temporarily discontinue topical beta-blockers in the contralateral eye. I also encourage behavior changes to help reduce aqueous egress, including strict instructions against eye rubbing, wearing an eye shield at night, and avoidance of Valsalva maneuver.

If hypotony is more profound, with marked shallowing of the anterior chamber and/or ciliary body detachment, viscoelastic can be injected into the anterior chamber.^{2,3} Injection may be done with a cannula through a previously created paracentesis or through clear cornea with a 25- to 30-gauge needle. Injection should be performed in a sterile manner with a lid speculum after prepping with povidone-iodine and instilling a topical antibiotic. The viscoelastic will increase IOP for 24 to 48 hours, which may allow additional bleb scarring or reattachment of the ciliary body and increased aqueous secretion. Healon (sodium hyaluronate) is a common initial choice, whereas Healon GV (sodium hyaluronate 1.4%) and Healon 5 (sodium hyaluronate 2.3%) will allow progressively more retention and ability to raise IOP. Often, viscoelastic injections need to be repeated several times until IOP is maintained spontaneously. If viscoelastic injection is done, the IOP should be checked 1 to 2 hours later

Stepwise Treatment of Overfiltration

1. Medical and behavior management
 - Taper topical steroids
 - Cycloplegia
 - Avoid eye rubbing and Valsalva, wear eye shield
2. Minor procedures
 - Viscoelastic injection
 - Blood injection
3. Major procedures
 - Resuture the scleral flap ± excise avascular conjunctiva
 - Graft material to seal flap, ± additional drainage surgery

to monitor for an IOP rise. Especially with Healon GV and Healon 5, IOP can rise very high and remain there for days, therefore, marked care must be used when using these high-viscosity agents after a trabeculectomy.

One option to induce bleb scarring is an autologous blood injection.⁴ Although I personally have found this to be rarely successful, it may be worthwhile in a few cases. After prepping the arm and eye with povidone-iodine, approximately 0.5 cc of blood is drawn from an antecubital or other convenient vein with an 18- to 20-gauge needle. The needle is changed to a 25-gauge, inserted subconjunctivally temporal to the bleb, and advanced to inject 0.1 to 0.5 cc of blood into and behind the bleb. The blood must be injected promptly following removal from the vein to avoid clotting in the syringe. HypHEMA is a common but self-limited complication.

Surgical Management

It is necessary to intervene surgically for hypotony that is threatening vision, however, this is uncommon.

Transconjunctival Scleral Flap Resuturing

The easiest technique is to directly resuture the scleral flap. If the bleb is not avascular and the scleral flap is visible, the flap may be resutured directly through intact conjunctiva using 10-0 nylon.⁵ The eye should be prepped sterilely, and a cotton-tip applicator can be used to push down and flatten the bleb overlying the scleral flap. The edges of the flap are then identified and sutured *tightly*. Over several days to a couple of weeks, the sutures will migrate into the bleb and become buried. As the bleb elevates again and tissue migrates out of the sutures, the sutures will loosen and the eye pressure will decrease.

Direct Scleral Flap Resuturing

More commonly, the scleral flap is resutured after opening conjunctiva. The conjunctival flap may be fornix- or limbus-based; it is often convenient to re-open the original conjunctival incision as long as the conjunctiva has not become avascular. Avascular tissue may not heal well and is prone to persistent leaks if incised. If avascular conjunctiva is believed to be playing a role in hypotony, it should be excised along with a narrow margin of healthy conjunctiva to ensure there is a bleeding, healthy, viable edge. The scleral flap is then identified, and if partially scarred down, may be sharply re-elevated and freshened. The flap should then be sutured tightly using 10-0 nylon to achieve a watertight (or nearly watertight) closure. The conjunctiva should then be closed in a watertight fashion, and suture lysis of the scleral flap sutures performed as needed. Achieving a controlled elevation of IOP in the early postoperative period may reverse some of the signs and symptoms of hypotony maculopathy and speed resolution of choroidal effusions.

Scleral Flap and Bleb Revision

Not infrequently, the scleral flap is found to be friable, partially "melted," or otherwise damaged from antimetabolite exposure and surgical manipulation, and it may be impossible to adequately restrict flow by resuturing the flap. These situations can be addressed by suturing graft material, typically sclera or pericardium, over the entire scleral flap site using 10-0 nylon. Although the graft should be sutured down tightly and securely, the closure may not need to be watertight because the new graft will typically scar down and permanently seal the old trabeculectomy site. Although some have tried to suture the new graft material in such a way to allow continued partial flow of aqueous posteriorly into the bleb, I have not found this technique to be successful.

As expected, covering the old trabeculectomy site frequently results in uncontrolled pressure. When sacrificing a bleb with graft material, I will frequently place a glaucoma tube shunt (typically a Baerveldt 350 mm² concomitantly to provide continuing control of IOP).

Choroidal Effusions

Although choroidal effusions are often approached as a distinct complication that requires directed treatment, I think it is better to consider them to be a complication of hypotony. I have found that drainage of choroidal effusions is rarely indicated. Rather, treatment of the underlying hypotony is typically curative.

Choroidal effusions themselves rarely cause permanent vision loss, although they are a risk factor for choroidal hemorrhage. Many effusions,

even relatively large ones, can be carefully observed, while waiting for medical management, to allow spontaneous hypotony resolution. If effusions are "kissing," if there is lens-cornea touch, or if chronic ciliary body detachment is contributing to hypotony, drainage may be indicated as part of trabeculectomy revision.

AQUEOUS MISDIRECTION

Assessment

Glaucoma surgery is one of the most common reasons that eyes develop aqueous misdirection. Aqueous misdirection was previously called "malignant glaucoma," a moniker it earned due to the extremely high rate of blindness that occurred before ophthalmologists learned to treat this condition. Today, prompt recognition and appropriate treatment of this condition should prevent serious vision loss in most circumstances.

Aqueous misdirection is classically recognized by a shallow to flat anterior chamber and marked elevation of IOP. However, functioning outflow surgery can significantly blunt or prevent the elevation in IOP secondary to aqueous misdirection. For example, a markedly shallow anterior chamber and an IOP of 16 mm Hg is highly suggestive of aqueous misdirection in the setting of recent trabeculectomy or tube shunt (by contrast, a shallow chamber of overfiltration would typically be associated with IOP in the low single digits). Because pupillary block and choroidal hemorrhage can also present with a shallowed chamber and elevated IOP, a patent iridotomy and complete fundus exam are important before making the diagnosis of aqueous misdirection.

Medical Management

Initial treatment for aqueous misdirection is intense cycloplegia, augmented by topical aqueous suppressants and acetazolamide. Systemic hyperosmotics (intravenous mannitol, 0.5 to 1.5 gm/kg or oral glycerine 1 to 1.5 gm/kg) can be effective but must be used cautiously due to their systemic side effects. Often, medical management alone is not sufficient.

Laser Management

In pseudophakia, aqueous misdirection will often respond to nd:YAG capsulotomy and anterior hyaloidotomy to disrupt the anterior hyaloid face. After performing a typical nd:YAG capsulotomy, additional laser shots can be applied into the anterior vitreous. If successful, the anterior chamber will begin to deepen rather quickly, typically while the laser is still being performed. Retinal tears are a small risk when lasering the vitreous body.

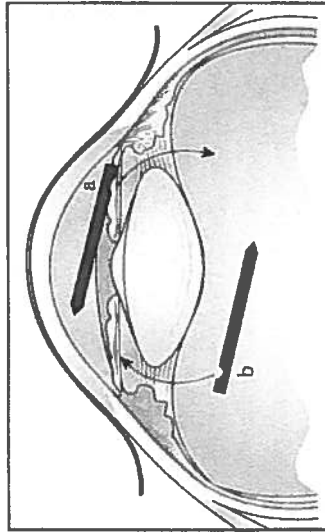


Figure 5-1. Surgical management of aqueous misdirection. An iridozonulohyaloidectomy (IZH) is performed by passing the vitrector through the iris, zonules, and anterior hyaloid. This maneuver can be approached from the (a) anterior chamber via a clear cornea incision or (b) through the pars plana.

Alternatively, the YAG laser can be applied through a peripheral iridectomy to disrupt the zonules as well as the anterior vitreous face. Again, however, this is typically helpful only in pseudophakias.

Surgical Management

Complete removal of the vitreous body by a pars plana vitrectomy is currently the gold standard for curing aqueous misdirection. The vitreoretinal surgeon must be sure to break the anterior hyaloid face, which can be difficult to do in phakic patients without damaging the lens capsule.

Rarely, aqueous misdirection can persist despite a complete pars plana vitrectomy, presumably due in part to the presence of the retained vitreous skirt. In these cases, an iridozonulohyaloidectomy (IZH; this term was coined by Ike Ahmed, MD) should be performed (Figure 5-1). This can be done by passing an automated vitrector from the posterior segment, up through the zonules and iris, into the anterior chamber (or similarly from the anterior chamber down through iris and zonules into the anterior vitreous). A combined pars plana vitrectomy and IZH are highly curative but can be performed only in pseudophakias or aphakes. In phakic patients, the lens may need to be removed to allow resolution of aqueous misdirection.⁶

Some anterior segment surgeons have found that performing a limited anterior vitrectomy and IZH has allowed them to successfully treat aqueous misdirection without involving a vitreoretinal surgeon. I typically do not do this myself, but rarely I utilize this maneuver for "intraoperative aqueous/infusion misdirection."

BLEB LEAK

Assessment

Although a bleb leak may lead to hypotony, the most serious complications are blebitis and endophthalmitis. It is for this reason that a frank bleb leak must always be treated.

A Seidel fluorescein test for leakage should be performed whenever a patient with a filtering bleb presents with epiphora, hypotony, or a low/flat bleb and hypotony. Additionally, it may be prudent to periodically check for leaks in high, thin avascular blebs.

Upon discovery of a leak, blebitis should be ruled out by ensuring there is no conjunctival injection, bleb infiltrate, or anterior chamber inflammatory cells. Initially, a simple bleb leak can be managed conservatively. The patient should be instructed to avoid touching the eye and practice good hygiene to avoid infection.

Medical Management

A majority of bleb leaks will resolve with conservative management, especially those leaks that occur in the early postoperative period. Shortly after a trabeculectomy, leaks will often respond to simply tapering topical steroids to allow scarring and healing.

Typically, when the leak is discovered, a topical antibiotic, such as a fourth-generation fluoroquinolone, is started to prevent the progression to blebitis. Although it is likely prudent to do so, it is not totally clear whether prophylactic antibiotics truly prevent blebitis or simply promote the emergence of a resistant organism.

Optimization of the ocular surface can help support healing of the leak. Erythromycin ointment or azithromycin gel, through their anti-inflammatory action and improvement in meibomian gland function, may help promote a healthy ocular surface and potential reepithelialization of the leak. Systemic doxycycline, up to 100 mg twice daily, can also improve ocular surface health in the same way. Additionally, its inhibition of matrix metalloproteinases may further promote closure of the leak.

The leak is likely kept open by continual aqueous flow through the conjunctival defect. Therefore, measures should be taken to reduce fluid egress through the leak. The patient should be instructed to avoid Valsalva, bending, and eye rubbing. Wearing an eye shield during sleep can be very helpful. To further reduce flow through the leak, aqueous suppressants can be tried.

Pressure-patching the eye for 24 hours may allow closure of the leak by temporally tamponading flow. Similarly, a bandage contact lens

may be placed to completely cover the leak. Because infection and corneal decompensation are the main risks of a bandage contact lens, a topical third- or fourth-generation fluoroquinolone needs to be added, and the patient should be examined at least weekly. Typically, I replace the bandage lens every 1 to 2 weeks and will allow 2 to 4 weeks for healing before abandoning the bandage lens.

Surgical Management

If the leak occurs in a localized bleb (one surrounded by a ring of scar tissue), needling may be tried to allow aqueous to diffuse more broadly and lower the pressure within the bleb. In some cases, this may promote closure of the leak and prevent a return to the operating room.

The simplest repair is suturing the leak. Suturing is most likely to be helpful in the early postoperative period when the conjunctiva is actively healing and when the leak occurs in the previous conjunctival incision line. However, because every needle pass can create more leaks, resuturing is not helpful for thinned or avascular tissue.

If the leak does occur with thinned conjunctiva, most likely the leak will have to be repaired by conjunctival advancement, which provides an acceptable level of safety and success.⁷ First, a peritomy is performed around the base of the bleb, taking care to keep the incision within bleeding, viable conjunctiva. Extensive undermining should then be performed to ensure fresh conjunctiva can be advanced to the limbus without tension. The avascular bleb tissue can then be deepithelialized with light cautery and the healthy conjunctiva advanced over the old bleb to the limbus. The closure should be as close to watertight as possible.

A few modifications to this technique may be helpful. The avascular, leaking bleb can be completely excised. Additional scleral flap sutures may be placed to reduce flow and promote healing of the newly advanced conjunctiva without leak; suture lysis may be performed a later date as necessary. If the conjunctiva cannot be closed without excessive tension, then a conjunctival autograft can be used or the bleb can be sacrificed by sealing it with donor graft material and placing a glaucoma tube shunt.

BLEBITIS

Assessment

Blebitis can rapidly progress to endophthalmitis and profound vision loss. Therefore, blebitis requires early recognition and aggressive management. The initial symptoms of blebitis are pain or discomfort, redness of the eye, and decreased vision. There may be antecedent epiphora from a bleb leak.

Signs on examination are injection of the bleb and/or surrounding conjunctiva, as well as a bleb infiltrate, giving the bleb a white or milky appearance. Occasionally, a hypopyon within the bleb can be seen. An anterior chamber reaction is common. If there are any vitreous inflammatory cells, retinal consultation should be obtained immediately to rule out endophthalmitis.

Management

If there is any question of blebitis, the patient should be started on a fourth-generation fluoroquinolone and rechecked in 24 hours or less. Alternatively, fortified antibiotics, typically vancomycin 25 to 50 mg/mL plus ceftazidime 50 mg/mL or tobramycin 14 mg/mL can be used for more assured microbial coverage (I tend to avoid the aminoglycosides, such as tobramycin, if there is any risk of intraocular penetration through a bleb leak due to their potential for extreme retinal toxicity). Typical dosing should begin with 1 drop every 15 minutes for the first hour, then 1 drop hourly thereafter. Subconjunctival injections of the same fortified antibiotics may be added if the patient's ability to fully adhere to the medical regimen is in doubt. Frequent follow-up is required to ensure the blebitis is resolving and not progressing to endophthalmitis.

If endophthalmitis is diagnosed, prompt treatment is essential. A pars plana vitrectomy is indicated earlier for a bleb-associated endophthalmitis than for a postcataract surgery endophthalmitis, although intravitreal antibiotic injections remain a viable alternative.

CHOROIDDAL HEMORRHAGE

Assessment

Choroidal hemorrhages occur most commonly in the setting of hypotony. Other risk factors are glaucoma, systemic hypertension, vascular disease, and eyes that have had prior vitrectomies.^{8,9} Systemic anticoagulation may not increase the risk of choroidal hemorrhage, but can make a small hemorrhage become one that is devastating.

Choroidal hemorrhages are recognized by pain and a dark choroidal mound on fundus examination. B-mode ultrasonography is confirmatory. Additional examination findings depend on the size of the hemorrhage and include shallowing or flattening of the anterior chamber, increased IOP, and variable loss of vision.

Management

Small, self-limited choroidal hemorrhages require observation only, along with instructing the patient to avoid Valsalva, eye rubbing, and,

if possible, systemic anticoagulation. Larger hemorrhages may benefit from cycloplegia and topical or systemic steroids. If the anterior chamber is severely shallow, if the choroidal hemorrhages are "kissing," or if IOP is uncontrolled, drainage is indicated. I typically refer patients to my vitreoretinal colleagues for drainage of choroidal hemorrhage, although some anterior segment surgeons prefer to perform the surgery themselves.

KEY POINTS

1. Hypotony can often be observed but needs to be treated when it is causing (or likely will cause) vision-threatening complications.
2. Most early postoperative hypotony will resolve spontaneously if given enough time; supportive measures can help buy time for early bleb scarring to bring up the IOP.
3. All bleb leaks need to be addressed, and conjunctival advancement is often the best choice for late-onset leaks when more conservative measures fail.
4. Successful management of aqueous misdirection may respond to Nd:YAG laser disruption of the anterior vitreous face but often requires a pars plana vitrectomy and/or an iridonzonulohyaloidectomy.

REFERENCES

1. Oyakhire JO, Moroi SE. Clinical and anatomical reversal of long-term hypotony maculopathy. *Am J Ophthalmol*. 2004;137(5):953-955.
2. Salvo EC Jr, Luntz MH, Medow NB. Use of viscoelastics post-trabeculectomy: a survey of members of the American Glaucoma Society. *Ophthalmic Surg Lasers*. 1999;30(4):271-275.
3. Hoffman RS, Fine IH, Packer M. Healon5 as a treatment option for recurrent flat anterior chamber after trabeculectomy. *J Cataract Refract Surg*. 2003;29(4):635.
4. Okada K, Tsukamoto H, Misumoto M, et al. Autologous blood injection for marked overfiltration early after trabeculectomy with mitomycin C. *Acta Ophthalmol Scand*. 2001;79(3):305-308.
5. Maruyama K, Shirato S. Efficacy and safety of transconjunctival scleral flap resection for hypotony after glaucoma filtering surgery. *Graefes Arch Clin Exp Ophthalmol*. 2008;246(12):175-176.
6. Tsai JC, Barton KA, Miller MH, Khaw PT, Hitchings RA. Surgical results in malignant glaucoma refractory to medical or laser therapy. *Eye (Lond)*. 1997;11(Pt 5):677-681.
7. Burnstein AL, WuDunn D, Knotts SL, Catoira Y, Cantor LB. Conjunctival advancement versus nonincisional treatment for late-onset glaucoma filtering bleb leaks. *Ophthalmology*. 2002;109(1):71-75.
8. Obushowska I, Mariak Z. Risk factors of massive suprachoroidal hemorrhage during extracapsular cataract extraction surgery. *Eur J Ophthalmol*. 2005;15(6):712-717.
9. Moshfeghi DM, Kim BY, Kaiser PK, Sears JE, Smith SD. Appositional suprachoroidal hemorrhage: a case-control study. *Am J Ophthalmol*. 2004;138(6):959-963.



GLAUCOMA DRAINAGE DEVICE IMPLANTATION

PREOPERATIVE EVALUATION FOR GLAUCOMA DRAINAGE DEVICE SURGERY

Joshua D. Stein, MD, MS

The success of glaucoma drainage device (GDD) surgery depends not only on the technical skills necessary to perform the surgery but also on careful preoperative planning. During the preoperative evaluation, the surgeon must determine whether the patient is a good candidate for the surgery. Moreover, the surgeon must consider whether GDD surgery is the most appropriate option for lowering intraocular pressure (IOP) or whether other medical or surgical procedures would be better choices. The preoperative evaluation can affect the decisions regarding which type of GDD to use during the surgery, the best location to implant the GDD, and it may identify patients at increased risk for intraoperative or postoperative complications. This chapter discusses information that should be gathered and reviewed by the surgeon before performing GDD surgery.

PATIENT HISTORY

Ocular History

It is important to take a thorough ocular history to identify prior conditions and previously performed surgical procedures that may complicate GDD surgery. Specific conditions that one should inquire about include conditions that can result in scarring of the bulbar conjunctiva, including prior eye trauma and incisional surgical procedures, such as trabeculectomy surgery, intracapsular or extracapsular cataract surgery, or strabismus surgery. Previously placed implants, such as scleral buckles, need to be noted preoperatively, as their presence may affect the location of GDD implantation,

or there may be extensive scar tissue around such devices, potentially preventing successful GDD implantation. If silicone oil or other substances that can obstruct the lumen of the GDD have previously been placed in the eye, these substances may need to be removed before a GDD can be successfully implanted. Other conditions, such as scleritis, ocular cicatricial pemphigoid, Stevens-Johnson syndrome, or chemical injuries can also cause thinning and scarring of the conjunctiva, which would make GDD surgery challenging, as would conditions that affect eyelid anatomy or the blink reflex. Whether a patient is phakic or pseudophakic and has undergone previous pars plana vitrectomy can also affect where the GDD can be inserted in the eye.

Medical History and Patient-Related Factors

The surgeon should inquire about acute and chronic medical conditions affecting the patient. For example, if a patient has an acute illness causing coughing, sneezing, nausea, or vomiting, it may be wise (when possible) to delay the GDD surgery, as these symptoms can cause sutures to break, wounds to dehisce, and can increase the risk for intraocular bleeding. Inquiring about chronic medical conditions such as obstructive pulmonary disease or back pain, which limit patients from lying flat on their back for the surgery, may affect the decision regarding the type of anesthesia to use for the surgery. Likewise, if a patient cannot lie still for prolonged periods of time due to Parkinson's or Alzheimer disease, this too can affect the type of anesthesia required. Patients who have a known history of poor adherence to glaucoma medication regimens need to be counseled about the importance of adhering to postoperative medication regimens to help reduce the risk for postoperative infection or inflammation.

Risk of Infection

Patients who are taking medications, such as corticosteroids or immunosuppressant agents, are at increased risk for infection during and after intraocular surgery. Persons who are immunocompromised are also predisposed to infection. Moreover, ocular conditions, such as blepharitis, can also lead to infection. In nonurgent surgeries, it is best to prophylactically treat conditions such as blepharitis to reduce the risk for serious infections (eg, endophthalmitis).

Risk of Hypotony

Patients with a history of chronic intraocular inflammation are at increased risk for ciliary body shutdown and postoperative hypotony after any intraocular surgery, including GDD implantation. Depending on the status of the patient's glaucoma, one may consider using a flow-restrictive

glaucoma drainage implant, such as an Ahmed GDD (New World Medical, Inc), or a smaller-sized non-flow-restrictive device, such as a Baerveldt-250 (Abbott Medical Optics [AMO]), instead of a Baerveldt-350 (AMO) GDD.¹

Risk of Bleeding

It is important to inquire about medical conditions and medications that can increase the risk for bleeding during surgery. Medical conditions associated with an increased risk for bleeding include liver disease, uremia, blood dyscrasias, and vitamin K deficiency. Medications that increase bleeding include aspirin, warfarin, and clopidogrel. Vitamins and supplements that can increase the risk for bleeding include vitamin E, ginkgo biloba, and garlic. Whenever possible, the patient should inquire with the medical provider who prescribed the medications about the possibility of discontinuing their use temporarily before surgery. If it is unsafe to discontinue use of these products, the surgery can still be performed, although the surgeon should be prepared to deal with any intra- and postoperative bleeding that may occur.

Risk of Suprachoroidal Hemorrhage

A serious, potentially sight-threatening complication of any intraocular procedure, including GDD surgery, is suprachoroidal hemorrhage. During the preoperative period, the surgeon should identify those patients who have multiple risk factors for this complication. Such risk factors include older age, arteriosclerosis, obesity, short axial length, high myopia, prior intraocular surgery (especially pars plana vitrectomy), use of blood-thinning agents, and a history of suprachoroidal hemorrhage.² In patients who have several of these risk factors, the surgeon should, whenever possible, try to prevent postoperative hypotony. Using flow-restrictive rather than non-flow-restrictive GDDs may be safer in these patients. Other techniques, such as injecting some viscoelastic into the anterior chamber at the end of the procedure or in clinic if profound hypotony occurs, can help reduce the risk for hypotony-related complications in these patients.

Patient Expectations

As part of the informed consent process before surgery, the patient needs to be made aware of the risks, benefits, and alternatives of performing the surgery. It is important to explain that it is not uncommon for patients to require one or more IOP-lowering medications, even if the surgery is successful and the GDD is functioning properly. Patients should also be informed that additional surgical interventions are necessary if the GDD becomes obstructed or does not sufficiently reduce the IOP. Discussing

these points with the patient ahead of time and taking the time to answer questions about the surgery during the preoperative period can help prevent the patient from entering into the surgery with unrealistic expectations.

PREOPERATIVE OCULAR EXAMINATION

Best Corrected Visual Acuity

When evaluating a patient for GDD surgery, the surgeon must gauge the patient's visual potential by assessing his or her best corrected visual acuity (BCVA). In general, GDD surgery is offered to patients who have reasonable visual potential. In eyes known to have poor visual potential, a less invasive surgical procedure, such as cyclophotocoagulation, may be a more appropriate strategy to lower the IOP. Obtaining an accurate preoperative visual acuity is also useful for determining whether the vision has returned to baseline during the postoperative period after GDD surgery. If the GDD surgery is uncomplicated, the BCVA should quickly return to the preoperative level or better (if the patient had decreased vision as a result of microcystic corneal edema associated with elevated IOP), often within the first week. A decline in BCVA after GDD surgery may alert the clinician to a postoperative complication, such as cystoid macular edema or corneal edema.

Refractive Error

With any intraocular surgical procedure, including GDD surgery, obtaining a manifest refraction during the preoperative period can alert the surgeon to a patient's increased risk for intra- or postoperative complications. For example, patients who have high levels of myopia are at increased risk for a retinal tear or detachment in the postoperative period. These patients would benefit from a careful evaluation of the peripheral retina before proceeding with GDD surgery. Likewise, patients who have high levels of hypermetropia may have nanophthalmos. To reduce the risk for postoperative choroidal effusions in eyes with nanophthalmos, the surgeon may plan to perform prophylactic sclerostomies immediately before implanting the GDD.

Ocular Motility

One of the complications of GDD surgery is extraocular muscle restriction, which can result in binocular diplopia. Determining whether the ocular motility is normal in the preoperative examination can help the clinician identify whether self-report of diplopia after the surgery can be attributed to the surgery or to a pre-existing ocular or systemic condition.

Eyelids

When evaluating whether a patient is an appropriate candidate for GDD surgery, his eyelid function must be considered. Implanting a GDD in eyes with lagophthalmos or exophthalmos can be problematic because the ocular surface in these patients is often inadequately lubricated. Such patients have an increased likelihood of experiencing breakdown of the conjunctiva overlying the GDD. Before proceeding with GDD surgery, these patients may first require surgery to address their eyelid abnormalities. Alternatively, if a patient has significant eyelid abnormalities that are not easily correctable, endoscopic or transscleral diode cyclophotocoagulation may be more appropriate than GDD surgery. Because patients can develop ptosis as a result of GDD surgery, the clinician should document the presence of any pre-existing ptosis found in the preoperative evaluation.

Conjunctiva

One of the most important factors to consider when evaluating patients for GDD surgery is the health of the bulbar conjunctiva. Careful inspection is required to evaluate the viability of the bulbar conjunctiva in the quadrant where the surgeon is considering implanting the GDD. This is particularly critical in patients who have risk factors for scarring, such as those with a history of intraocular surgery, ocular trauma, or an acid or alkali burn. Extensive conjunctival scarring in the quadrant under consideration may make it technically challenging for the surgeon to adequately mobilize enough healthy conjunctival tissue to completely cover the implant and overlying patch graft. If conjunctival scarring is identified preoperatively, the surgeon may elect to implant the GDD in a different quadrant that has healthier bulbar conjunctival tissue. If considerable conjunctival scarring is present, the surgeon may need to perform a conjunctival autograft with tissue from an adjacent quadrant or from the contralateral eye. Alternatively, it may be preferable to consider performing a cyclodestructive procedure instead of attempting GDD surgery in these patients. In addition to visual inspection of the bulbar conjunctiva to identify scar tissue, one can instill a topical anesthetic in the eye and then gently manipulate the conjunctiva with a cotton tip applicator to get a sense of how adherent it is to the underlying sclera.

Sclera

Evaluating the quadrant where the GDD will be implanted for scleral thinning is necessary to avoid scleral perforation during the surgery. If the sclera is too thin, as a result of scleromalacia or other causes, it may be unsafe to attempt to implant a GDD in the affected quadrant. It is also

useful during the preoperative period to check for evidence of previously created sclerostomies from prior glaucoma or retinal procedures. The surgeon would want to avoid prior trabeculectomy flaps and other sclerostomies during implantation of the GDD by rerouting the tube away from these locations. Inserting the tube through a previously created sclerostomy may lead to leakage of aqueous around the lumen of the tube, resulting in postoperative hypotony.

Cornea

During preoperative examination of the cornea, the surgeon should pay careful attention to the corneal endothelium. Corneal guttae on the surface of the endothelium may be a sign of Fuchs' endothelial dystrophy. Patients with Fuchs' endothelial corneal dystrophy are at increased risk for corneal decompensation after GDD surgery. In these patients, and with other patients who will likely undergo endothelial or penetrating keratoplasty in the future, the surgeon should plan to position the GDD as far away from the corneal endothelium as possible. If the patient is pseudophakic or aphakic, the surgeon should make every attempt to implant the GDD in the posterior chamber, and, if the patient had previous pars plana vitrectomy surgery, positioning the GDD in the vitreous cavity can reduce the risk for corneal decompensation after GDD surgery. It is also useful for the clinician to examine the cornea for scarring, as this may limit visualization of the tip of the tube both during the surgery and in the postoperative period. Often, patients with markedly elevated IOP before GDD surgery have microcystic corneal edema present. In these patients, temporarily lowering the IOP preoperatively with the use of aqueous suppressants and oral or intravenous carbonic anhydrase inhibitors may help clear up the edema and improve visualization of the tip of the tube during the surgery.

Anterior Chamber

When assessing the anterior chamber, one should take note of the anterior chamber depth and the presence of material in the anterior chamber that can get into and occlude the tube once it is inserted in the eye. There are several conditions that can result in the presence of a shallow anterior chamber. Individuals with high levels of hypermetropia often have short axial lengths and shallow anterior chambers. Persons who are phakic and who have large lenses that cause bulging forward of the iris can also exhibit shallowing of the anterior chamber. Scarring from previous intraocular surgery or trauma can result in iridocorneal touch, which can limit the depth of the anterior chamber. In all of these scenarios, it may be technically challenging to position the tip of the tube in the anterior chamber far

enough away from the corneal endothelium. When possible, addressing the underlying condition (eg, by performing laser peripheral iridotomy or cataract extraction) may be necessary prior to or concurrent with GDD implantation. Materials that can occlude the lumen of the GDD include vitreous, fibrin, or blood. If these substances are known to be present during the preoperative examination, the surgeon may need to address them before implanting the GDD into the eye, by performing a vitrectomy to remove vitreous or an anterior chamber washout to remove extensive hemorrhage or fibrin. In patients with active uveitis, use of topical, subconjunctival, or sub-Tenon's corticosteroids during the preoperative period and at the time of surgery can limit postoperative inflammation.

Iris

If neovascularization of the iris is present in the preoperative evaluation, an injection of an anti-vascular endothelial growth factor (VEGF) agent should be considered. These agents can reduce the risk for intra- and postoperative bleeding during GDD surgery, and, occasionally, anti-VEGF agents can cause regression of neovascularization of the angle and resolution of the IOP elevation, thus negating the need for GDD surgery.³ If anterior segment neovascularization is noted, the surgeon may consider indirect panretinal photocoagulation concurrent with GDD surgery. If the surgeon notes signs of iridocorneal endothelial (ICE) syndrome during the preoperative examination, he or she should try, whenever possible, to implant the GDD into the posterior chamber to reduce the chance that ICE material can proliferate into the lumen and obstruct the GDD.

Status of the Lens

When planning for GDD surgery, the surgeon should take note of whether the patient's eye is phakic, pseudophakic, or aphakic. Patients who are phakic should be informed that the surgery can hasten the development of cataracts. In addition, the surgeon should try to leave the tip of the tube short so that it will not get in the way during future cataract surgery. In patients who are phakic, it is necessary to implant the GDD in the anterior chamber. In patients with pseudophakia or aphakia, the surgeon may want to consider implanting the GDD into the posterior chamber, to reduce the risk for postoperative corneal decompensation in high-risk patients, such as those with Fuchs' endothelial dystrophy.

Intraocular Pressure

All patients who are being considered for GDD surgery have levels of IOP that are higher than desirable, which increases their risk for irreversible

glaucomatous damage. During the preoperative evaluation, the surgeon should think about whether there is a need for short-term IOP control, long-term IOP control, or both. All patients who present with extensive glaucomatous damage will require long-term IOP control. However, there will be a subset of these patients who have such extensive damage to their optic nerve already or a high enough IOP that they are also at risk for vision loss in the short term if the surgeon implants a nonvalved GDD; it takes weeks before the GDD becomes functional. Other patients may present with a markedly elevated IOP, as a result of anterior segment neovascularization, uveitis, or exposure to corticosteroids, but the eye care provider has identified the problem before any glaucomatous damage has occurred. In this subset of patients, the goal of GDD surgery is to immediately lower the IOP to a safer level; yet, achieving a very low IOP over the long term may not be necessary because these patients have healthy nerves with little or no damage. In patients who present with markedly elevated IOP and require short-term IOP control, implanting a flow-restrictive GDD, such as an Ahmed FP7 (New World Medical, Inc), can be effective at immediately lowering the IOP. If the surgeon prefers to implant a nonvalved GDD, such as a Baerveldt GDD, because these devices are tied off for the first few weeks after implantation, venting slits must be created in the lumen of the GDD to help regulate the IOP in the short term until it is safe to open the tube. There is some evidence that GDDs with larger plates can achieve a lower IOP in the long term than can other devices with smaller plates. An ongoing randomized clinical trial is testing this theory.⁴ Assuming this theory is correct, many surgeons prefer to implant GDDs that have larger-sized plates, such as the Baerveldt-350, in patients with advanced glaucoma who require a long-term low target IOP (in the low teens or lower), rather than devices with smaller-sized plates, such as an Ahmed GDD. Many of these patients can tolerate an IOP that is slightly above target for a few weeks after GDD implantation as they wait until it is safe for the tube to open and aqueous to flow through the GDD.

A small subset of patients have advanced glaucoma requiring long-term IOP control from a GDD with a larger plate size (eg, a Baerveldt-350), yet the preoperative IOP is also so high, or the damage to the optic nerve so advanced, that it would be too risky to implant a nonvalved GDD and simply wait a few weeks before the IOP can be lowered by opening the GDD. The surgeon has several options for managing these patients. One option is to implant a nonvalved Baerveldt-350 GDD and create venting slits in the lumen of the tube, with the hope that the venting slits will effectively lower the IOP in the short term until it is safe for fluid to flow through the GDD and collect around the plate. A second option is to combine the implantation of the Baerveldt-350 with an orphan trabeculectomy; one that is performed

for the sole purpose of achieving an immediate lowering of IOP during the postoperative period until the GDD becomes functional. A third option is to perform a double-tube surgery, simultaneously implanting a Baerveldt-350 in the superotemporal quadrant to achieve long-term IOP control and an Ahmed S3 in the superonasal quadrant that, along with the use of aqueous suppressants, can achieve short-term IOP control until the Baerveldt-350 becomes functional. A fourth option is to implant a biplate Ahmed GDD. These devices contain a flow-restrictive element so that the IOP can be lowered immediately, but they also have 2 plates and thus a larger surface area for aqueous to accumulate, providing long-term IOP control.

Extent of Glaucomatous Damage

When evaluating a patient for GDD surgery, the surgeon must carefully consider the extent of glaucomatous damage present. Patients who have elevated IOPs with minimal or no damage to the optic nerve and retinal nerve fiber layer may not require a very low IOP during the postoperative period. In contrast, those who have extensive visual field loss and cupping of the optic nerve may require very low target pressures after the surgery. According to preliminary results of the Ahmed Baerveldt Comparison Trial, patients with extensive damage who require a very low IOP after GDD surgery may do better with a Baerveldt-350 than an Ahmed GDD.⁵

Retina

In patients who are undergoing GDD surgery for neovascular glaucoma, it is useful to inspect the retina to determine whether the patient would benefit from concomitant panretinal photocoagulation along with the GDD implantation.

Gonioscopy

Before proceeding with GDD surgery, it can be helpful to perform gonioscopy to identify the presence of peripheral anterior synechiae in the region of the drainage angle where the GDD will be implanted. In patients with pseudophakia, who have extensive peripheral anterior synechiae, the surgeon can avoid the synechiae and position the tube tip away from the corneal endothelium by implanting the GDD in the posterior chamber rather than the anterior chamber. Sulcus placement of the GDD can be ideal in this situation. In patients with neovascular glaucoma, preoperative gonioscopy can identify areas of active angle neovascularization, so these locations can be avoided during tube insertion. Patients with Fuchs'

heterochromic iridocyclitis are also at increased risk for bleeding with GDD implantation, and gonioscopy can alert the surgeon to be prepared for this postoperative complication.

Hardware

During the preoperative assessment, the surgeon should check that there are no pieces of hardware, such as scleral buckle elements, present in the location where the plate of the GDD will be attached to the globe. If the patient has a scleral buckle present, the surgeon should consult with a retina specialist to determine whether it is safe, if necessary, to remove the element to free up space for the GDD. Some of the more modern scleral buckles may not require removal, as often the plate of the GDD can be positioned posterior to the buckle or sewn to the buckle element itself. If silicone oil is present in the eye, it will likely need to be removed before GDD implantation because it can obstruct the GDD or exit the eye via the GDD. **IF MUST PLACE IMPLANT IN EYE \bar{c} S.O. I THEN PLACE TUBE INFERO-NASAL.**

KEY POINTS

1. Decisions made during the preoperative evaluation can play an important role in the ultimate success of GDD surgery.
2. Factors affecting the decision about what type of GDD implant to use include the extent of glaucomatous damage present, the target IOP desired, the absolute level of IOP at the time of surgery and whether the eye can likely sustain this level of pressure for several weeks after implantation of a non-flow-restrictive device, and the type of glaucoma.
3. Important factors that affect the location of GDD placement in the eye include the presence of conjunctival scarring from prior surgery, whether the patient is phakic or pseudophakic, the depth of the anterior chamber, whether the eye has previously undergone pars plana vitrectomy, and the presence of previously placed hardware, such as scleral buckle elements.
4. Surgeons should plan ahead and, on occasion, modify their technique in patients at increased risk for infection, hypotony, bleeding, or suprachoroidal hemorrhage. Whenever possible, discontinuation of the use of medications that may predispose patients to intraoperative or postoperative bleeding should be considered.
5. Prior to proceeding with GDD surgery, it is essential to take the time to have a discussion of the risks, benefits, and alternatives of the surgery with the patient, to answer questions she may have, and to help set realistic expectations.

REFERENCES

1. Schwartz KS, Lee RK, Gedde SJ. Glaucoma drainage implants: a critical comparison of types. *Curr Opin Ophthalmol*. 2006;17(2):181-189.
2. Jeganathan VS, Ghosh S, Ruddle JB, et al. Risk factors for delayed suprachoroidal haemorrhage following glaucoma surgery. *Br J Ophthalmol*. 2008;92(10):1393-1396.
3. Duch S, Buchacra O, Milla E, et al. Intracameral bevacizumab (Avastin) for neovascular glaucoma: a pilot study in 6 patients. *J Glaucoma*. 2009;18(2):140-143.
4. Barton K, Gedde SJ, Budenz DL, Feuer WJ, Schiffman J, Ahmed Baerveldt Comparison Study Group. The Ahmed Baerveldt Comparison Study: methodology, baseline patient characteristics, and intraoperative complications. *Ophthalmology*. 2011;118(3):435-442.
5. Budenz DL, Barton K, Feuer WJ, et al. Treatment outcomes in the Ahmed Baerveldt Comparison Study after 1 year of follow-up. *Ophthalmology*. 2011;118(3):443-452.

TYPES OF GLAUCOMA DRAINAGE IMPLANTS







Jeffrey M. Zink, MD

INTRODUCTION

Two basic types of glaucoma drainage implants are used in glaucoma surgery. One type that has no valve, and 1 type that has a valve mechanism to moderate against hypotony. Both types have a silicone tube that is attached to a plate with a 0.3mm-lumen.¹ The Baerveldt (Abbott Medical Optics, Abbott Laboratories Inc., Abbott Park, Illinois) and Molteno (Molteno Ophthalmic Limited, Dunedin, New Zealand) glaucoma drainage implants do not have a valve to restrict flow, and typically require a ligation suture to restrict flow in the early postoperative period to avoid hypotony. The first tube shunt equipped with a valve was the Krupin Valve (E. Benson Hood Laboratories, Inc., Pembroke, Massachusetts) in 1976, which is a tube attached to a plate with a unidirectional valve. Ahmed valve implants (New World Medical Inc., Rancho Cucamonga, California) are now the most commonly utilized glaucoma drainage implant equipped with a valve.

In both valved implants and nonvalved implants there exists a variety of sizes and, in some models, different implant material composition. Increasing the size of the glaucoma drainage implant plate is a strategy that has been used to try and achieve better intraocular pressure (IOP) lowering results. Heuer et al² showed lower postoperative IOPs in patients that received double-plate (270mm²) compared to single-plate (135 mm²) Molteno implants. Alternatively, Britt et al³ found no additional IOP lowering benefit of the Baerveldt 500 mm² as compared to the 350 mm² in a randomized clinical trial. This suggests that there may be a benefit of lower IOP with increasing implant surface area to a certain degree, but this advantage is not necessarily consistent as implant size increases. Table 7-1 illustrates the characteristics of some of the most commonly used glaucoma drainage implants.⁴

TABLE 7-1. CHARACTERISTICS OF MOST COMMON GLAUCOMA DRAINAGE IMPLANTS

Device	Model	Device Image	Surface area	Side to side	Front to back	Implant profile	Single quadrant insertion	Plate material	Drainage tube	Fixation holes	Manufacturer
Ahmed	S2		184 mm ²	13 mm	16 mm	1.9 mm	Yes	Rigid polypropylene	Valved	Yes	New World Medical, Inc
	FP7		184 mm ²	13 mm	16 mm	0.9 mm	Yes	Smooth silicone	Valved	Yes	New World Medical, Inc
Molteno	D1		133 mm ²	13 mm	13 mm	1.65 mm	Yes	Rigid polypropylene	Open	Yes	Molteno Ophthalmic, Ltd
	Molteno3		175 mm ²	14.2 mm	13.6 mm	1.5 mm	Yes	Polypropylene	Open	Yes	Molteno Ophthalmic, Ltd
Baerveldt	BC 103-250		250 mm ²	22 mm	14 mm	0.84 mm	Yes	Smooth silicone	Open	Yes	Abbott Medical Optic
	BC 101-350		350 mm ²	32 mm	15 mm	0.84 mm	Yes	Smooth silicone	Open	Yes	Abbott Medical Optic

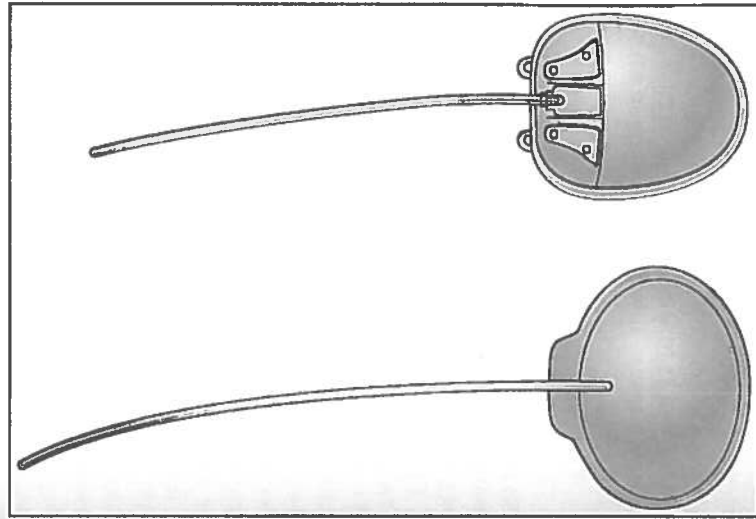


Figure 7-1. Krupin valve (left) and Ahmed valve (right). Both models contain a flow-restrictive valve designed to minimize the risk of hypotony.

VALVED IMPLANTS

Valved implants were designed to lower the risk of hypotony by having a pressure valve that only lets fluid through the tube and into the subconjunctival space of the implant plate when the IOP exceeds around 8 to 11 mm Hg, depending on the type of the valved implant. They also provide the advantage of lowering pressure sooner, because there they are designed to establish filtration immediately upon insertion (Figure 7-1).

Ahmed Glaucoma Drainage Implant

Ahmed glaucoma drainage implants are made with either polypropylene or silicone for the plate body composition. The characteristics of the plate material are thought to have some effect on the capsule that forms over the plate. It has been shown that the polypropylene endplate of the Ahmed

glaucoma valve induces greater amount of inflammation than the silicone end plate of the Baerveldt implant in the rabbit subconjunctival space.⁵ The amount of inflammation generated by different biomaterials may influence capsular thickness and resistance characteristics, which can affect IOP. Clinically, it has been shown that the popular Ahmed model FP7 may provide better pressure control when compared to the Ahmed S2 polypropylene model.⁶

Because the valve mechanism is designed to reduce the chance of hypotony, valved implants are well suited for patients with compromised aqueous secretion. Patients with uveitis, ciliary body ischemia or fibrosis, and prior cyclodestructive procedures are good candidates for a valved implant, such as the Ahmed. Valved implants can also be ideal for patients that need immediate IOP lowering with a very high preoperative IOP (eg, neovascular glaucoma). The Ahmed silicone models include the FP7 (Flexible plate), FP8 (Flexible plate pediatric), FX1 (Flexible bi-plate), PC7 (FP 7 model with pars plana clip), and PC8 (FP 8 model with pars plana clip). The polypropylene models include the S2 (Ahmed glaucoma valve), S3 (Pediatric glaucoma valve), B1 (bi-plate), PS2 (S2 model with pars plana clip), and the PS3 (S3 model pediatric with pars plana clip).

Krupin Valve

Krupen et al⁷ introduced the unidirectional, pressure-sensitive valve in 1976. The Krupin valve is designed to open at a pressure of 11 mm Hg and close at a pressure of 9 mm Hg.⁸ This was the first valved implant to reduce the incidence of early postoperative hypotony following aqueous drainage implant surgery.⁸ This valve has become less popular with the advent of the Ahmed glaucoma valve, which was introduced in 1993.

Nonvalved

Nonvalved implants do not contain a valve that restricts flow through the tube. As described previously, the nonvalved implants must be flow-restricted to allow time for adequate capsule formation and prevent immediate postoperative hypotony. Nonvalved implants can achieve immediate postoperative IOP control when tube fenestrations are performed. Tube fenestrations allow aqueous to drain from the tube, and into the subconjunctival space anterior to the suture ligation.⁹ Although fenestrations are often helpful, they are not necessarily the most consistent way to lower pressure, as there is always some variability of the magnitude and the duration of their effect. Some surgeons prefer to combine a trabeculectomy with insertion of the nonvalved ligated implant to achieve immediate postoperative pressure control. This can be a very reliable way to titrate IOP when immediate pressure lowering is desired and the surgeon prefers the insertion of a nonvalved implant (Figure 7-2).

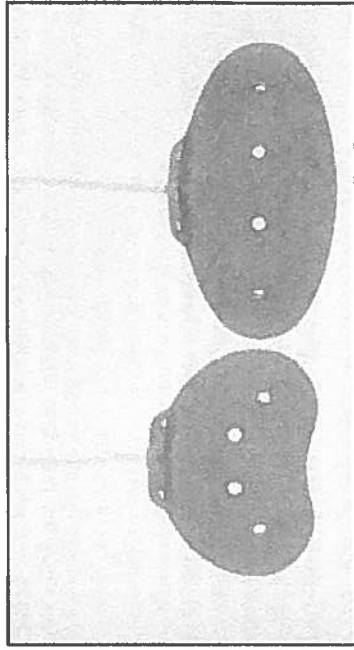


Figure 7-2. Baerveldt implant models 250 mm² (left) and 350 mm² (right) versions. These implants lack a flow-restrictive valve and require flow restriction in the early postoperative period to minimize the risk of hypotony. (Reprinted with permission from Allingham R, ed. *Shields Textbook of Glaucoma*. 6th ed. Philadelphia, PA: Lippincott Williams & Wilkins; 2011.)

Baerveldt

The Baerveldt glaucoma drainage implant has a large surface area plate attached to a tube for aqueous drainage. The Baerveldt implant is made of thin, durable, and flexible silicone material that is barium impregnated.¹⁰ This implant is designed to maximize filtration surface area, while still allowing single quadrant insertion. There are 3 types of Baerveldt glaucoma drainage implants: The Baerveldt 101-350, the Baerveldt 103-250, and the 102-350 designed for pars plana insertion. The Baerveldt 101-350 has a 350 mm² surface area and is larger than the 103-250 that has a 250 mm² plate surface area. The Baerveldt 101-350 is a popular model, and the drainage implant plate is usually placed underneath the rectus muscles.

The Baerveldt 102-350 has a 350 mm² plate, as well as a smaller plate attached to the tube that is sutured to the sclera in the area of the pars plana. This smaller plate has a Hoffman elbow design that allows direct insertion of the tube into the pars plana, and is done through a 20-gauge pars plana sclerostomy incision.

All Baerveldt implants are designed with holes in the plate. The holes allow fibrous tissue to grow through and are designed to achieve a lower bleb profile and minimize extraocular muscle disturbances. The Baerveldt implant's lower profile enables it to be used in the inferior nasal or inferior temporal quadrant quite easily. A retrospective, noncomparative case series demonstrated the effectiveness of the Baerveldt glaucoma implant in the

inferonasal quadrant.¹¹ I prefer the inferior nasal quadrant as my second choice for tube location next to the superior temporal quadrant when placing a Baerveldt implant.

Molteno

The Molteno glaucoma implant is another popular aqueous drainage implant design without a valve mechanism. Molteno implants come in multiple designs and have been studied for over 30 years in the management of glaucoma. In a rabbit model in 1969, Molteno first introduced the concept of a translimbal tube attached to an acrylic plate to facilitate aqueous drainage.¹⁷

Single-Plate Molteno

The Molteno single-plate design is ideal for single quadrant use and is relatively easy to insert with a relatively small conjunctival dissection. This is the original aqueous drainage implant design.

Double-Plate Molteno

The double-plate Molteno has a larger surface area, which is ideal when more IOP lowering effect is desired. This implant has the flexibility of additional postoperative control. The tube connecting the two plates, or the tube entering the eye, can be ligated with a temporary or permanent suture.¹³ A ligature suture applied to the connecting tube can restrict excess flow to the second plate, which can give the surgeon more control over the amount of aqueous drainage depending on a patient's pressure lowering needs.

Molteno3

The newer Molteno3 has a more flexible, larger plate than the earlier designs, and has an oval subsidiary ridge designed to form a biological valve to reduce postoperative hypotony.¹³ The biological valve works by limiting aqueous flow to the primary area of drainage until IOP increases to the point where the resistance of the overlying tissue is overcome, allowing aqueous drainage to expand over the whole plate.¹³ The use of the biological valve on the Molteno3 is intended for glaucomas with very high preoperative IOPs, where acute pressure lowering is needed. It can be helpful in cases where a traditional valved shunt may become occluded by clot or fibrin, such as neovascular or inflammatory glaucomas. Hypotony can still be seen in the early postoperative period with this device if it is not ligated. Therefore, in most routine glaucoma cases, the Molteno3 is ligated similar to a nonvalved shunt and the biological valve mechanism is not utilized in the early postoperative period.

Schocket

The Schocket glaucoma implant, also known as the ACTSEB (anterior chamber tube shunt to encircling band), was described by Schocket et al.¹⁴ for the treatment of neovascular glaucoma. The Schocket implant technique utilizes a silastic tube used for nasolacrimal intubation (diameter 0.30 mm). One end is placed underneath and sutured into the groove of a #20 retinal encircling band that is placed underneath the rectus muscles. The other end is placed into the anterior chamber to allow aqueous outflow to the capsule that forms around the encircling band. Modifications of the Schocket technique have been reported using smaller buckle element segments.¹⁵ This implant type has the advantage of being relatively inexpensive and can be used in places where glaucoma drainage implants are difficult to obtain, such as in developing countries. However, this implant is currently rarely used due to the existence of more modern implant designs.

OTHER IMPLANTS

Ahmed implants also have 2 commercially available models of nonvalved implants: a silicone nonvalved flexible plate implant (the FX4), and a polypropylene nonvalved model (the B4).

KEY POINTS

1. Nonvalved implants require a ligature suture, sometimes combined with a stent suture, to restrict flow in the early postoperative period.
2. Valved implants establish flow immediately and do not require a ligation suture.
3. IOP control may be influenced by the size of the glaucoma drainage implant plate, up to a certain point.
4. The type of material of the glaucoma drainage implant plate (silicone versus polypropylene) may influence the capsule characteristics and affect IOP control.
5. Smaller implants are available for pediatric glaucoma cases.
6. Pars plana models are available in the Baerveldt and Ahmed implants.

REFERENCES

1. Sidoti P. Glaucoma drainage implants. In: Morrison JC, Pollack IC, eds. *Glaucoma: Science and Practice*. New York, NY: Thieme; 2002:481.
2. Heuer DK, Lloyd MA, Abrams DA, et al. Which is better? One or two? A randomized clinical trial of single-plate versus double-plate Molteno implantation for glaucomas in aphakia and pseudophakia. *Ophthalmology*. 1992;99(10):1512-1519.
3. Britt MT, LaBree LD, Lloyd MA, et al. Randomized clinical trial of the 350-mm² versus the 500-mm² Baerveldt implant: long term results. Is bigger better? *Ophthalmology*. 1999;106(12):2312-2318.

4. Kahook, MY, Noecker RJ, Pantcheva MB, Schuman JS. Location of glaucoma drainage devices relative to the optic nerve. *Br J Ophthalmol*. 2006;90(8):1010-1013.
5. Ayyala RS, Harman LE, Michelini-Norris, et al. Comparison of different biomaterials for glaucoma drainage devices. *Arch Ophthalmol*. 1999;117(2):233-236.
6. Ishida K, Netland, PA, Costa VP, Shrioma L, Khan B, Ahmed II. Comparison of polypropylene and silicone Ahmed Glaucoma Valves. *Ophthalmology*. 2006;113(8):1320-1326.
7. Krupin T, Podos SM, Becker B, et al. Valve implants in filtering surgery. *Am J Ophthalmol*. 1976;81(2):232-235.
8. Hong C, Arosemena A, Zurakowski D, Ayyala S. Glaucoma drainage devices: a systematic literature review and current controversies. *Surv Ophthalmol*. 2005;50(1):48-60.
9. Emerick GT, Gedde SJ, Budenz DL. Tube fenestrations in the Baerveldt glaucoma implant surgery: 1-year results compared with standard implant surgery. *J Glaucoma*. 2002;11(4):340-346.
10. Baerveldt glaucoma implant [package insert]. Kalamazoo, MI: Abbott Medical Optics & Upjohn, Inc; 2000.
11. Harbick KH, Sidoti PA, Budenz DL, et al. Outcomes of inferonasal Baerveldt glaucoma drainage implant surgery. *J Glaucoma*. 2006;15(1):7-12.
12. Molteno ACB. New implant for draining in glaucoma. *Br J Ophthalmol*. 1969;53(3):161-168.
13. Molteno Ophthalmic Web site. <http://www.molteno.com/>.
14. Schocket SS, Nirankari VS, Lakhnani V, et al. Anterior chamber tube shunt to an encircling band in the treatment of neovascular glaucoma. *Ophthalmology*. 1982;89:1188-1194.
15. Omi CA, Almeida GV, Cohen R, Mandia C, Kwitko S. Modified Schocket implant for refractory glaucoma. *Ophthalmology*. 1991;98(2):211-214.

8

STANDARD TECHNIQUE FOR IMPLANTING GLAUCOMA DRAINAGE DEVICES

Joshua D. Stein, MD, MS

This chapter will review a basic step-by-step technique for implantation of non-flow-restrictive (eg, Baerveldt) and flow-restrictive (eg, Ahmed) glaucoma drainage devices (GDDs). The chapter will cover suggested instruments used to perform each step of the procedure, a description of how to perform each step of the surgery, the rationale for why each step of the procedure is performed, and a description of some pearls and pitfalls associated with each step of the procedure. The focus of this chapter is the description of the basic technique for GDD implantation. Please see subsequent chapters for a description of modifications of the techniques described below to address more complicated situations that one may encounter when performing GDD surgery.

OBTAINING ADEQUATE EXPOSURE

Adequate exposure is essential when performing GDD surgery. Two options are available for improving exposure. One option is to place a traction suture through the superior cornea. A 7-0 polyglactin suture is passed through the peripheral cornea at the 12 o'clock position. For inferior tube placement, an inferior corneal traction suture can be placed in a similar fashion at the 6 o'clock position. Care should be taken not to take too deep a pass and penetrate into the anterior chamber. If the patient has had a prior penetrating keratoplasty or other incisional corneal surgery, the corneal traction suture should be placed in a manner to avoid these sites. An alternative option to a corneal traction suture is to place the suture around the superior rectus muscle. After the traction suture is placed, the eye is rotated inferonasally to maximize exposure to the superotemporal bulbar

conjunctiva. The traction suture is secured to the operative drape with a hemostat. A corneal protector is then placed over the cornea to protect it during the procedure and reduce retinal exposure to bright light from the operating microscope. Placement of viscoelastic beneath the corneal shield in patients with severe surface disease or corneal pathology can help to reduce the chance of a corneal epithelial defect developing during surgery.

CONJUNCTIVAL INCISION

The technique I prefer is to create a conjunctival peritomy 5 mm posterior to the limbus. A caliper is used to measure 5 mm posterior to the limbus in the superotemporal quadrant. Using nontoothed forceps, such as Pierce-Hoskins forceps (Katena Eye Instruments, Denver, New Jersey) or Max Fine forceps (Altomed, Boldon, United Kingdom), the bulbar conjunctiva is gently tented up, and an incision is made through the conjunctiva with Westcott scissors. Using the Pierce-Hoskins forceps to hold up the conjunctiva adjacent to the incision, use Westcott scissors through the conjunctival incision to perform blunt dissection of the surrounding bulbar conjunctiva. Extend the initial conjunctival incision temporally and superiorly for 2 clock hours. The incision should follow the curve of the limbus. When extending the incision laterally and superiorly, the surgeon should be careful not to cut the superior or lateral recti muscles. Next, grasp Tenon's capsule with the Pierce-Hoskins forceps and cut through it with Westcott scissors down to bare sclera. After Tenon's tissue has been cut, it is best (whenever possible) to avoid grasping the conjunctiva until the time of closure so this tissue does not become damaged. Instead of grasping conjunctival tissue, grasp Tenon's tissue with the Pierce-Hoskins forceps and use the Westcott scissors to perform blunt dissection to create a pocket in the superotemporal quadrant for the implant to be placed (Figure 8-1). Enter with the curved Stevens scissors (Katena Eye Instruments) and continue with blunt dissection. Adequate blunt dissection is achieved when one can insert closed curved Stevens scissors into the superotemporal quadrant and open them wide with little resistance. If bleeding is encountered during the blunt dissection, use cautery to achieve hemostasis. Instead of performing the conjunctival peritomy 5 mm posterior to the limbus as described above, an alternative technique is to create the conjunctival peritomy directly at the limbus. → **PREFERRED BY UPMC FACULTY**

IF USING SUB-TENON ANESTHESIA, MUST ANESTHETIZE CONJUNCTIVA. FIRST USING LIDO JEEL OR SUBCONJ LIDO.

My preference for anesthesia is to provide a sub-Tenon's injection of 3 to 4 cc of a 50/50 mixture of 2% lidocaine and 0.5% bupivacaine in the superotemporal quadrant around the superior and lateral rectus muscles. This should be done with a curved blunt-tip cannula (an olive tip works well). When injecting the anesthesia using the dominant hand,

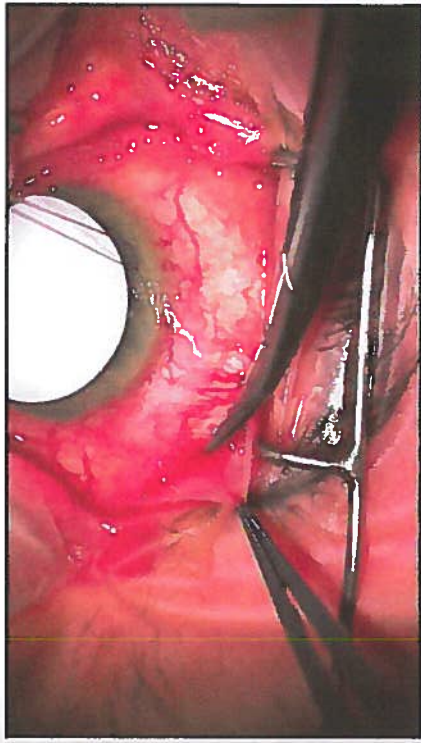


Figure 8-1. Conjunctival dissection. An incision through the bulbar conjunctiva was made 5 mm posterior to the limbus in the superotemporal quadrant. Pierce-Hoskins forceps are used to grasp Tenon's tissue, and Westcott scissors are used to perform blunt dissection separating the bulbar conjunctiva and Tenon's tissue from the underlying sclera.

simultaneously use a Pierce-Hoskins forceps with the nondominant hand to press down on the conjunctiva, which helps trap the anesthetic in the desired location. An alternative means of anesthetizing the eye for the GDD surgery would be to perform a peribulbar or retrobulbar block prior to beginning the surgery.

PREPARING THE GLAUCOMA DRAINAGE DEVICE FOR IMPLANTATION

Ahmed Glaucoma Drainage Device

Ahmed glaucoma drainage devices (models S2, FP7, and S3) contain a built-in element that acts like a one-way valve to restrict the flow of aqueous through the implant. Before an Ahmed glaucoma drainage device can be implanted into the eye, it is necessary to first prime the tube. Priming involves injecting balanced salt solution through the tube to assure tube patency. A 27- or 30-gauge cannula is attached to the tip of the tube. Balanced salt solution is injected through the tube. As one presses down on the plunger to flush the tube with balanced salt solution, one should encounter moderate resistance. If there is little or no resistance (ie, balanced salt solution exits through the tube with little or no force exerted on the plunger of the cannula), the implant may be defective. If it is inserted into the eye

309
15
EASER.

←
STEADILY INCREASE PRESSURE ON THE PLUNGER UNTIL YOU FEEL TUBING THE EYE. REINSTATE

and the flow restrictive element is not properly restricting flow, the patient is at risk for postoperative hypotony. If extensive resistance is encountered during flushing with balanced salt solution, this may also indicate a defective flow-restrictive element, and if the tube is implanted, it may be non-functional. In either case, if the tube does not flush properly, ask for a new GDD and send the defective one back to the manufacturer.

Baerveldt Glaucoma Drainage Device

Baerveldt glaucoma drainage devices (models BG 103-250 and BG 101-350) do not contain a flow-restrictive element. However, they still need to be primed with balanced salt solution to verify the patency of the tube. A 27-gauge cannula is attached to the tip of the tube. There should be no resistance when balanced salt solution is passed through the tube.

Next, a piece of 6-0 Prolene (Ethicon, Somerville, New Jersey) or 5-0 nylon suture is passed through the lumen of the Baerveldt implant.¹ This piece of suture will serve as a ripcord that will allow the surgeon a means of opening the implant at the slit lamp during the postoperative period, thus making it functional. Although some surgeons elect not to use a ripcord with this procedure, I routinely use ripcords because it allows me to control the precise timing of the opening of the tube. Without a ripcord, if the 7-0 polyglactin ligature obstructing the GDD is not easily accessible to be able to apply laser to dissolve the suture in the clinic during the postoperative period (because it is covered by a scleral patch graft), the tube will open spontaneously and the surgeon will be unaware if the intraocular pressure becomes too low, putting the patient at increased risk for complications associated with hypotony.

The final step in preparing a Baerveldt GDD is to tightly tie off the tube using a piece of 7-0 absorbable polyglactin suture so that no aqueous can exit through the tube until a capsule has formed around the plate. Because Baerveldt implants have no mechanism to restrict the flow of aqueous, if a capsule of tissue has yet to form around the plate, the patient will experience hypotony during the immediate postoperative period if the tube is not tied off completely. To help assure that the tube is completely tied off and will remain so until a capsule has formed, the tube is tied off with the 7-0 polyglactin suture by using at least 3 knots. I routinely use 6 knots to tie off the tube to be absolutely sure it will not open prematurely. Next, the cannula containing balanced salt solution is reattached to the tip of the tube. An attempt is made to forcefully pass balanced salt solution through the occluded tube. With forceful irrigation, if the surgeon is able to pass balanced salt solution through the occluded tube, this indicates that it is not completely occluded. Additional 7-0 polyglactin sutures should be placed adjacent to the first suture and tied off in the same manner described above.

THIS STEP IS OFTEN OMITTED

WE DO NOT TYPICALLY PERFORM A RIPCORD OCCLUSION

USE TWO NEEDLE DRIVERS TO TIGHTLY TIE THE KNOT

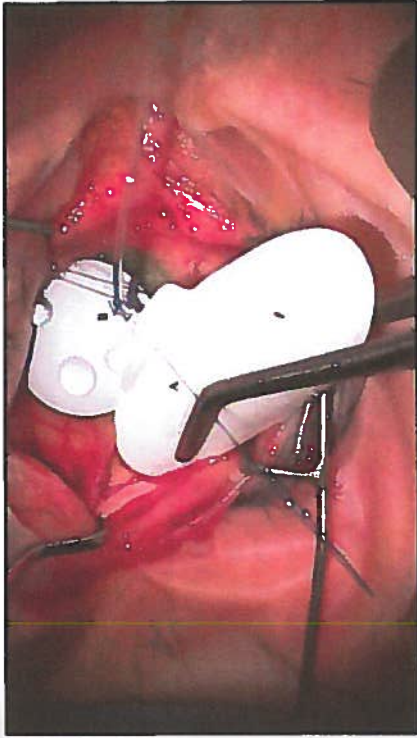


Figure 8-2. Preparing a Baerveldt 350 glaucoma drainage device for implantation. In preparation for implanting a Baerveldt 350 glaucoma drainage device, after flushing the tube with balanced salt solution, a 6-0 Prolene suture has been inserted through the lumen of the tube (A) and the tube is tied off with 7-0 polyglactin suture (B). The surgeon grasps the implant with Nugent forceps and is about to position it under an extraocular muscle.

Repeated testing with balanced salt solution should be performed until the surgeon is unable to forcefully pass any balanced salt solution through the tube, indicating it is completely occluded (Figure 8-2).

SECURING THE PLATE OF THE IMPLANT TO THE SCLERA

Ahmed Glaucoma Drainage Device

Ahmed GDDs are small enough that the plate can fit in between the superior and lateral rectus muscles. When grasping the Ahmed GDD to position it in the superotemporal quadrant, care should be taken to avoid touching the valvular element because it can easily get damaged. With the nondominant hand, the surgeon should use Pierce-Hoskins forceps to grasp and retract back the Tenon's tissue, exposing the underlying bare sclera in the superotemporal quadrant. Using Nugent forceps, the surgeon should grasp the plate of the Ahmed implant behind the valvular element and place it in the superotemporal quadrant between Tenon's tissue and bare sclera. When positioning the plate in the superotemporal quadrant, if resistance is encountered, one may need to perform additional blunt dissection using the Westcott or curved Stevens scissors. Next, the surgeon should use a caliper

CAN ALSO USE 0.3 OR 0.5 FORCEP

to mark the sclera 8 mm posterior to the limbus in the superotemporal quadrant. It is important that the plate is secured at least 8 mm posterior to the limbus, as a more anterior placement of the plate can increase the risk of developing delten during the postoperative period. Next, the surgeon should pass a 9-0 nylon suture through the sclera, at least 8 mm posterior to the limbus. Although it is important to take an adequate bite of sclera with the suture pass so that the suture does not cheese-wire through the sclera when it is tied off, one needs to be careful not to take too deep of a pass through the sclera so that the suture penetrates the choroid or retina. After taking the scleral bite, the suture should then be passed through the eyelet of the implant and tied off. A second 9-0 nylon suture should be passed through the sclera and then through the other eyelet and tied off. Tying forceps are then used to bury the knots within the eyelets to reduce the risk of them eroding through the conjunctiva during the postoperative period. After the plate is secured to the underlying sclera, calipers should be used to verify that the plate is situated at least 8 mm posterior to the limbus. If the implant is more anterior than 8 mm, one or both of the nylon sutures may need to be cut and resecured further back from the limbus.

Baerveldt Glaucoma Drainage Device

Baerveldt glaucoma drainage devices have a larger surface area relative to Ahmed glaucoma drainage implants and must be positioned under the insertions of the superior and lateral rectus muscles. The Baerveldt 250 implant can be positioned with 1 wing under either the lateral or superior rectus muscle, whereas the Baerveldt 350 model is larger and needs to be positioned with both wings under the recti muscles. In general, this implant is designed to be placed underneath the extraocular muscles, but it can also be placed on top of the muscles in special circumstances, such as with prior strabismus surgery or traumatic globe injuries. In these cases, the normal extraocular muscle anatomy can be significantly disrupted, making standard placement underneath the muscles difficult or impossible.

Before attempting to place the implant in the superotemporal quadrant, the surgeon should use a muscle hook to identify and isolate the superior and lateral rectus muscles. It is important to clean and check ligaments beneath the muscles to ensure that the wing of the implant passes freely underneath the muscle. Next, with the nondominant hand, the surgeon should use Pierce-Hoskins forceps to grasp and retract back the Tenon's tissue, exposing the underlying bare sclera in the superotemporal quadrant. With the dominant hand, the surgeon should next isolate and hook either the superior or lateral rectus muscles. After the muscle is hooked, the surgeon should hold the hooked muscle with the nondominant hand, freeing

the dominant hand to be able to position the plate of the implant under the muscle. Using Nugent forceps, the surgeon should grasp the plate of the Baerveldt implant and place 1 wing of the plate behind the hooked rectus muscle. After the wing is situated behind the rectus muscle, the surgeon can release the hooked muscle and slide the muscle hook out from between the rectus muscle and wing of the plate. When removing the muscle hook, care should be taken to ensure that the wing of the Baerveldt remains properly positioned posterior to the rectus muscle.

When implanting the Baerveldt 350 model implant, the surgeon must next isolate and hook the second rectus muscle with the muscle hook. After this muscle is hooked, the plate of the implant is manipulated so that the second wing is positioned posterior to the hooked rectus muscle. When the wing is visualized behind the insertion of the rectus muscle, the hooked rectus muscle can be released and the muscle hook can be slid out from between the rectus muscle and the wing of the plate. Before securing the plate to the underlying sclera, the surgeon can check to verify that both wings of the implant are posterior to the recti muscles by grasping one of the eyelets with ~~0-12~~ forceps and tugging the plate toward the limbus. If both wings of the plate are posterior to the muscle insertions, resistance will be met when attempting to tug the plate more anterior toward the limbus. If there is little or no resistance with this maneuver, it may indicate that one or both of the wings may not be posterior to the rectus muscles, and the plate will need to be repositioned before it can be secured to the sclera.

Next, the surgeon should use calipers to mark the sclera 8 mm posterior to the limbus in the superotemporal quadrant. It is important that the plate is secured at least 8 mm posterior to the limbus, as a more anterior placement of the plate can increase the risk of developing delten or plate erosions during the postoperative period. The surgeon should then pass a 9-0 nylon suture through the sclera, at least 8 mm posterior to the limbus. Although it is important to take an adequate bite of sclera with the suture pass so that the suture does not cheese-wire through the sclera when it is tied off, one needs to be careful not to take too deep of a pass through the sclera so that the suture penetrates the choroid or retina. After taking the sclera bite, the suture should then be passed through the eyelet of the implant and tied off. A second 9-0 nylon suture should be passed through the sclera and then through the other eyelet and tied off. Tying forceps are then used to bury the knots within the eyelets to reduce the risk of them eroding through the conjunctiva during the postoperative period. After the plate is secured to the underlying sclera, the calipers should be used to verify that the plate is situated at least 8 mm posterior to the limbus. If the implant is more anterior than 8 mm, one or both of the nylon sutures may need to be cut and resecured further back from the limbus. For placement of Baerveldt GDDs in the inferonasal and inferotemporal quadrants, a similar technique is

USE 0.3
OR 0.5
FORCEP!

WE COMMENT
DO NOT
SECURE
BOTH
EYELETS
(SOMETIMES
NEITHER!)

followed except that the wings of the implant are placed beneath the inferior rectus and corresponding medial or lateral rectus muscles.

ADDITIONAL CONJUNCTIVAL DISSECTION

The bulbar conjunctiva adjacent to the limbus can be thin and friable, and after it is dissected away from the underlying sclera it can lose its viability if it dries out. For this reason, I find it useful to hold off performing blunt dissection of this tissue away from the underlying sclera until after the plate is secured to the sclera. Using Westcott scissors, blunt dissection of the conjunctiva and Tenon's tissue is performed all the way anterior up to the limbus. Additional blunt dissection can be performed by using Weck-Cel spears (Medtronic, Jacksonville, Florida) to gently lyse any additional adhesions that are present at the limbus. It is important to exert care when manipulating this tissue so it does not tear. If bleeding is encountered, cautery should be applied, when necessary, to achieve hemostasis. If there is scar tissue at the superotemporal limbus from prior intraocular surgery, the tube may need to be rerouted to adjacent tissue, which may be more viable. Likewise, if there is a prior trabeculectomy flap present in the superotemporal quadrant, care should be taken to avoid routing the tube through the flap of the trabeculectomy. Note, this step is not necessary if the initial conjunctival incision was performed at the limbus rather than 5 mm posterior to the limbus.

TRIMMING THE TUBE

Corneal traction is released so that the eye can return to its normal position and the surgeon can determine the optimal location to trim the tube. Release of corneal traction is important because if the surgeon trims the tube while the eye is torqued inferonasally without accounting for this, the tip of the tube may end up too long in the anterior chamber after traction is released. If the tube needs to be rerouted around scar tissue, this should be taken into consideration when deciding the location to trim the tube, as it may need to be longer to account for such rerouting. With the nondominant hand, the tube is grasped with tying forceps and Westcott or Vannas scissors are used with the dominant hand to trim the tube in a manner so that a sharp bevel is created (Figure 8-3). It is important not to forcefully tug the tube toward the center of the cornea when grasping it with the nondominant hand prior to trimming it, as this can cause the surgeon to inadvertently trim the tube so that it is too short. When trimming the tube, one should err on the side of too long rather than too short. If it is too long, it can always be trimmed shorter, whereas if the tube is trimmed too short, a tube extender may be required to lengthen it.

TUBE EXTENDERS ARE CHALLENGING AND MORE PRONE TO POST-OP

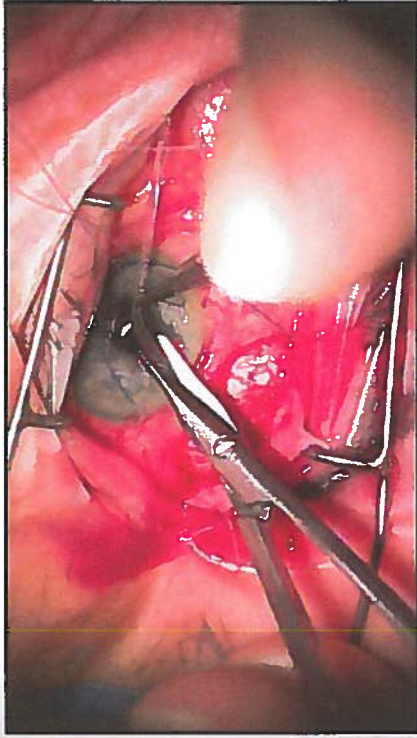


Figure 8-3. Trimming the tube. Westcott scissors are used to trim the tube to the proper length. When trimming the tube, by positioning the Westcott scissors in a plane that is nearly parallel to that of the tube, the surgeon is able to create a sharp bevel, which can facilitate insertion of the tube through the sclerostomy.

BEVEL AWAY FROM I215?

If the plan is to insert the tube into the anterior chamber, one should trim the tube so that it will extend 2 to 3 mm into the anterior chamber with its bevel directed upward. If the tube is trimmed too short, there is a possibility it may retract posteriorly during the postoperative period and out of the anterior chamber. If the tube is trimmed too long, it increases the risk of the tip contacting the corneal endothelium, which would lead to corneal decompensation. If the plan is to insert the tube into the posterior chamber, the surgeon should create a downward rather than an upward bevel and should trim the tube so that it is longer. If the tube is cut short, it will be completely hidden behind the iris after it is inserted into the posterior chamber. By trimming the tube longer, it will be easier to visualize the tip of the tube during the postoperative period. If the plan is to insert the tube into the vitreous cavity to facilitate visualization of the tube tip, the surgeon should trim it so that it will extend at least 6 mm within the vitreous cavity. In eyes with prior vitrectomy, a longer tube in the vitreous cavity will also reduce the risk of tube occlusion from retained vitreous. This can happen in the setting of an incomplete vitrectomy where the vitreous skirt may not have been adequately trimmed prior to the tube insertion.

PARACENTESIS

A 75/15 blade or microvitrectomy blade is used to create a paracentesis through temporal clear cornea. The purpose of creating a paracentesis is so that the surgeon can easily access the anterior chamber to reinflate the

anterior chamber with balanced salt solution if it gets too shallow or to insert a cyclodiagnosis spatula in the event that the tip of the tube happens to get stuck in the iris during insertion. The paracentesis also gives the surgeon access to the anterior chamber in the early postoperative period to acutely lower or raise the intraocular pressure (IOP) by "burping" aqueous from the paracentesis or injecting viscoelastic through the paracentesis in the setting of profound hypotony.

SCLEROSTOMY

Arguably, the most important step of the surgery is the creation of the sclerostomy, as this will determine where the tube will be positioned within the eye. The sclerostomy is created with a 22- or 23-gauge needle. An advantage of using a 22-gauge needle to create the sclerostomy is that it creates a larger sclerostomy so that it is easier to insert the tube into the anterior chamber. A disadvantage of a larger-size sclerostomy is that aqueous can exit through the sclerostomy around the lumen of the tube, increasing the risk of postoperative hypotony. For this reason, I prefer using a 23-gauge needle to create the sclerostomy. Although it creates a sclerostomy with a tighter fit, there is less room for aqueous to exit through the sclerostomy around the tube and thus a reduced risk of postoperative hypotony.

For implantation of the tube into the anterior chamber, I choose an entry site as anterior to the limbus as possible approximately at the 10:30 or 11 o'clock position when operating on a right eye; I use 1 o'clock for left eyes. If a buttonhole is present in the overlying conjunctiva at the planned site of the sclerostomy, I will create the sclerostomy at a different location to avoid the conjunctival buttonhole. If the plan is to place the tube into the posterior chamber, I create the sclerostomy 2 mm posterior to the limbus, whereas if the plan is to implant the tube into the vitreous cavity, the sclerostomy should be created 3.5 mm posterior to the limbus. When creating the sclerostomy, the 23-gauge needle should be grasped with its bevel upward. To assure proper positioning of the tube in the anterior chamber, it is helpful to enter with the needle into the anterior chamber following a pathway that is parallel to the plane of the iris (Figure 8-4). If the needle does not enter parallel to the iris plane, the tip of the tube may end up positioned against the corneal endothelium, which can increase the risk of corneal decompensation, or with the tube tip embedded into the iris stroma so that aqueous is unable to exit through the tube. If the patient is phakic, care should be taken when creating the sclerostomy not to enter too deep into the anterior chamber with the needle so as to risk damaging the lens or lens capsule. When placing the tube into the vitreous cavity, the needle should be oriented so the tube will be positioned just anterior to the center of the vitreous cavity.

can inject a small amount of vitreous into the sclerostomy tract as you withdraw the needle.

A

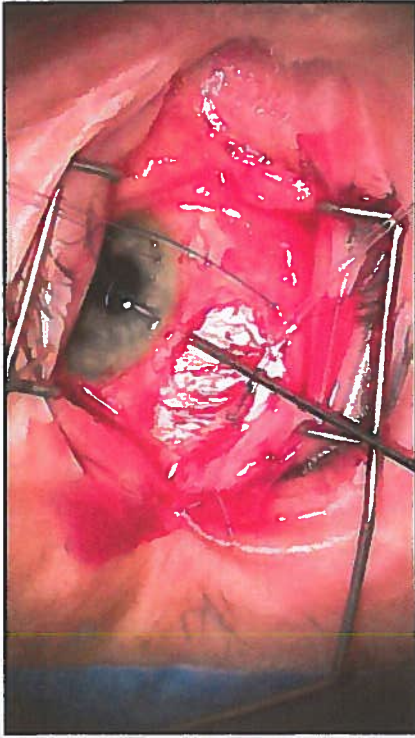


Figure 8-4. Creating the sclerostomy. A 23-gauge needle is used to create a sclerostomy. The angle of entry of the needle into the anterior chamber should be parallel to the plane of the iris with the bevel of the needle positioned upward.

TUBE INSERTION THROUGH THE SCLEROSTOMY

Once the sclerostomy is created, the next step is to insert the tube through the sclerostomy. Gently retract the bulbar conjunctiva adjacent to the sclerostomy toward the limbus so it is not in the way during the tube insertion. Grasp the tube at its bevel with a tube introducer or angled Kelman forceps (Katena Eye Instruments) and insert the bevel completely into the sclerostomy. *unnecessary with limbal peritomy* *to facilitate the insertion, hold the bevel of the tube in the sclerostomy for 20 to 30 seconds before re-grasping the tube slightly posteriorly and continue pushing the tube into the sclerostomy.* Continue passing the tube through the sclerostomy until it can be visualized in the anterior chamber. Watch the tip of the tube as it enters into the anterior chamber to be sure that it is properly positioned in the anterior chamber. If the tip of the tube gets embedded in the iris, it can often be repositioned by inserting a cyclodiagnosis spatula through the paracentesis and sweeping the tip away from the iris. *SCLEOSTOMY MAY SELF-SEAL IF 2ND TRACT IS ADJACENT* If the tube tip is visualized abutting the peripheral cornea, the tube will need to be pulled back out through the sclerostomy. The sclerostomy sutured shut, and a new sclerostomy created. If the tube tip is visualized to be too long, it should be pulled back out of the sclerostomy, trimmed to the proper length, and reinserted. *TRIM & REINSERT*

SECURING THE TUBE TO SCLERA

To aid in the remaining steps of the surgery, the eye should again be rotated inferonasally and held in this position using the traction suture.

Once the tube is visualized to be properly positioned within the eye, the exposed portion of the tube is secured to the underlying sclera using a 9-0 nylon suture by creating a figure-of-eight knot. Care should be taken not to penetrate the lumen of the tube when passing this suture.

↳ ISS/KVM ROUTINELY DO SUTURE THROUGH THE TUBE VENTING SLITS

Because Baerveldt implants are completely tied off, until the ripcord is pulled and the tube is opened or the tube opens spontaneously, the IOP will continue to remain elevated during the immediate postoperative period. Some surgeons elect to make 1 to 5 small punctures into the lumen of the tube between the sclerostomy and the plate that serve as venting slits to help lower the IOP during the immediate postoperative period.³ The venting slits are created by using a spatulated needle. A TG-140 needle works well.

COVERING THE TUBE WITH A PATCH GRAFT

To prevent the tube from eroding through the overlying bulbar conjunctiva, it is strongly recommended to cover the exposed tube from the plate to the sclerostomy with a patch graft.³ Different materials including donor sclera, donor cornea, or Tutoplast (New World Medical, Inc) can be used as a patch graft to cover the exposed tube. The most important portion of the tube requiring coverage with the patch graft is the site where the tube enters into the sclerostomy. The patch graft can be tacked down to the underlying sclera by using 2 to 4 7-0 polyglactin sutures (Figure 8-5). When securing the patch graft to the underlying sclera, care should be taken not to penetrate the lumen of the tube.

MAY NOT NEED TO SUTURE PATCH (IF USING TISSUE)

CONJUNCTIVAL CLOSURE

Prior to reapproximation of the conjunctival wound during Baerveldt implant surgery, one will need to trim the ripcord and tuck it under the bulbar conjunctiva before closing the conjunctival wound if the ripcord technique was used. The ripcord should be tucked under the conjunctiva in a location where it is easy to get to at the slit lamp, such as under the temporal bulbar conjunctiva, close to the limbus.

To reapproximate the conjunctiva, the posterior edge of the bulbar conjunctival wound is grasped with 2 Pierce-Hoskins forceps and gently shimmed forward so it can be sutured to the anterior edge of the bulbar conjunctival wound. Two to 3 evenly spaced interrupted 8-0 polyglactin sutures on a vascular needle are used to secure the 2 edges of the conjunctival wound. Next, the conjunctival wound is reapproximated by using a running locked 8-0 polyglactin suture on a vascular needle. During wound

TYPICALLY SECURE 8-0 VASCULAR NEEDLES, MAKE SURE TISSUE (LIMBUS) CLOSURE

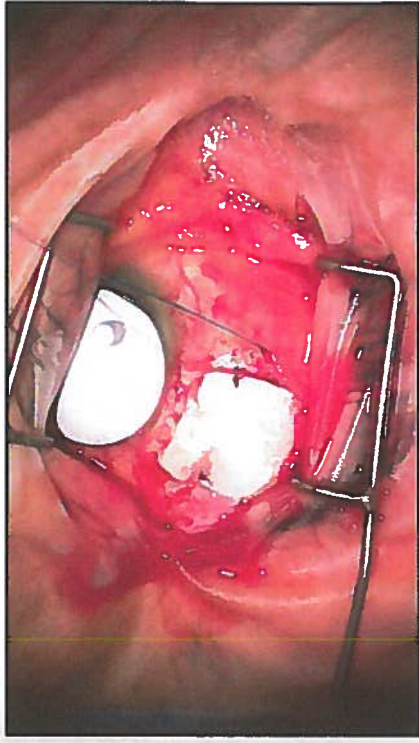


Figure 8-5. Covering the tube with a scleral patch graft. A scleral patch graft covers the tube its entire length from the plate to the sclerostomy. The patch graft has been secured in place by using two 7-0 polyglactin sutures. The 6-0 Prolene ripcord can be seen to the right of the scleral patch graft.

closure, it is very important to be sure that one is reapproximating bulbar conjunctiva to bulbar conjunctiva and not conjunctiva to Tenon's tissue.

COMPLETION OF THE SURGERY

At the conclusion of the surgery, one should inspect the depth of the anterior chamber and evaluate whether the IOP is physiologic. The traction suture is removed. A fluorescein strip is used to check the conjunctival wound and paracentesis site for leaks. A subconjunctival injection of steroids and antibiotics is given inferiorly. In cases of uveitic or neovascular glaucoma, a drop of atropine 1% can be helpful to help maximize the anterior chamber depth and stabilize the blood-ocular barrier. The eyelid speculum is removed. The eye is dressed with bacitracin or erythromycin ointment and closed. A patch and metal shield are placed over the eye for protection.

TYPICALLY USE ATROPINE FOR PATCH SURGERY (AIMED)

KEY POINTS

1. When preparing a non-flow-restrictive implant such as a Baerveldt GDD or Molteno GDD, it is essential that the tube is completely tied off before such devices are implanted into the eye. Without complete ligation of these devices, all of the aqueous can escape through the GDD, resulting in hypotony with a shallow or flat anterior chamber. These patients are at significantly increased risk for experiencing serious sight-threatening complications such as suprachoroidal hemorrhage.

2. One of the most important steps of GDD surgery is the creation of the sclerostomy through which the GDD will course into the eye. The entry should be parallel to the plane of the iris. An entry that is too anterior can result in the tip of the tube adjacent to the cornea, increasing the risk of corneal decompensation. If the entry is too posterior, the tube tip may become embedded in the iris.
3. When trimming the GDD to the proper length, one should err on the side of leaving the tube tip too long, as it is much easier to trim the tube further than to risk creating a tube that is too short.
4. When covering the tube with a patch graft, it is important to attain complete coverage of the exposed tube from the sclerostomy site to the site where the tube attaches to the plate.

REFERENCES

1. Lerner SF, Parrish RK. Glaucoma aqueous humor drainage devices. In: Chen TC, ed. *Glaucoma Surgery*. Philadelphia, PA: Lippincott Williams & Wilkins; 2003:111-125.
2. Fechter HP, Lee PP, Walsh MM. Non-valved single-plate tube shunt procedures: Baerveldt and Molteno implants. In: Chen TC, ed. *Glaucoma Surgery*. Philadelphia, PA: Elsevier Inc.; 2008:87-121.
3. Raviv T, Greenfield DS, Liebmman JM, Sidoti PA, Ishikawa H, Ritch R. Pericardial patch grafts in glaucoma implant surgery. *J Glaucoma*. 1998;7(1):27-32.

9

LOCATION OF GLAUCOMA DRAINAGE IMPLANTS AND TUBES

Gabriel T. Chong, MD and Richard K. Lee, MD, PhD

Glaucoma drainage implants (GDIs) are an important treatment modality for glaucoma, especially for refractory types, such as neovascular and uveitic glaucomas. Organic materials (eg, horse hair and silk) or inert materials (eg, gold and platinum) were used as conduits to shunt aqueous from the anterior chamber to the subconjunctival space at the limbus as early GDIs prior to the 1900s.¹ The nonvalved Molteno implant was the first widely used GDI device of the modern era.² Shortly thereafter, Krupin developed a valved glaucoma implant to reduce the risk of early hypotony.¹ The Ahmed and Baerveldt GDIs were introduced in the 1990s and are now also widely used.¹

REASONS FOR GLAUCOMA DRAINAGE IMPLANTS

Although trabeculectomy with antifibrotic agents remains a common IOP-lowering glaucoma surgery worldwide, glaucoma patients with high risk for surgical failure (eg, uveitic and neovascular glaucoma) can achieve long-term intraocular pressure (IOP) control with GDI surgery. The Tube Versus Trabeculectomy (TVT) study's 1-year results indicated comparable IOPs with GDIs compared with trabeculectomies, with a trend toward fewer reoperations in the GDI group.³ The TVT study also suggested that GDIs are less likely to cause hypotony-related issues and are more likely to achieve IOP control compared with trabeculectomies.³ GDIs also offer good IOP control in refractory glaucomas, such as those associated with uveitis, trauma, epithelial and fibrous downgrowth, aniridia, and iridocorneal endothelial syndromes, whereas trabeculectomy is frequently less successful.⁴

TYPES OF GLAUCOMA DRAINAGE IMPLANTS

GDI's in popular use include the nonvalved single- and double-plate Molteno, the nonvalved Baerveldt, the valved Ahmed, and the valved Krupin glaucoma drainage implants.¹ The first widely used GDI was the Molteno implant, which has a round polypropylene end plate with a surface area of 134 mm² for the single plate and 268 mm² for the double plate GDI. The rounded plates of the double-plate Molteno implant are connected by a 10-mm silicone tube.⁴ The Ahmed valved implant is made from either polypropylene (models S2, S3, and B1) or silicone (models FP7, FP8, and FX1).⁴ Different plate sizes are available with surface areas ranging from 96 mm² (S3 and FP8) to 184 mm² (S2 and FP7) to 364 mm² (B1 and FX1).⁴ The Ahmed valve mechanism consists of 2 thin membrane-like elastomer sheets, which, in principle, restrict flow until a pressure of greater than 8 to 12 mm Hg is experienced intraocularly.⁴ The Krupin slit valve consists of an oval silastic disc (13 × 18 mm)⁵ with an area of 183 mm².⁴ The pressure is regulated by horizontal and vertical slit valves. As an alternative, the tube end may be connected to a #220 silastic band. The Baerveldt nonvalved GDI plate is a barium-impregnated X-ray-visible smooth and flexible silicone plate that comes in 2 sizes—plate areas of 250 mm² or 350 mm² (the larger 500 mm² model was discontinued).⁶ The plate has fenestrations to allow bridging superior and inferior plate surface fibrous strands to develop, thereby reducing the vertical profile of the resultant bleb from 10.6 mm to 4.9 mm.⁷

Several GDIs offer multiple plate options, such as for the Molteno and the Ahmed. Various studies have shown that the larger the end plate size, the larger the surface area of encapsulation around the plate and thus the greater the degree of IOP reduction with a greater surface area of filtration.⁸ Although larger surface area may be better for IOP lowering, an upper limit beyond which a larger size plate may not lead to lower IOP exists, and larger plates may lead to more surgical complications.⁷

The profile of each type of GDI ranges from a flatter 0.84 mm for the 2 Baerveldt plate sizes and 0.9 mm for the silicone FP7 Ahmed, to a higher profile for the Ahmed S2 (which is 1.9 mm high) and the Krupin (which is 1.75 mm high).^{5,6} Capsule profile height is an important consideration because patient comfort and ocular motility may be decreased by greater plate height. Depending on the quadrant of GDI implantation, cosmesis may also be affected.

The composition of the plate affects capsule formation. A prospective, comparative study in which polypropylene Ahmed and silicone GDIs were compared showed a greater incidence of Tenon cysts formation in the polypropylene group, and better IOP lowering was observed with the silicone plate group.⁹ The more rigid polypropylene Ahmed plate is also believed to

cause more movement of the plate against the globe, which can stimulate a more aggressive inflammatory reaction and thicker capsule wall formation associated with higher IOP outcomes. The more flexible silicone plate is suggested to reduce formation of thick filtering capsules. Also, valved GDIs have immediate fluid drainage to the plate, which may induce thicker capsule formation compared with nonvalved GDIs, with which aqueous flow is occluded until after capsule formation.¹⁰ Cosmetically, this information is useful when choosing the quadrant of insertion for a GDI because thicker, higher capsules may be less desirable in the inferior quadrants. A lower-profile Baerveldt implant may be a better choice than an Ahmed for inferior quadrant placement.

OCULAR ANATOMY AND ORBITAL CONSIDERATIONS FOR GLAUCOMA DRAINAGE IMPLANT PLACEMENT

Of the 4 orbital quadrants available for GDI placement, the most common and recommended site is the superotemporal quadrant. Key reasons for this recommendation include ease of plate implantation access in this quadrant for the surgeon, avoidance of the oblique extraocular muscles, and available conjunctival tissue for plate and tube coverage. The various GDI plate placement locations in the 4 orbital quadrants in relation to the limbus and the optic nerve were studied in human cadaver eyes. The Ahmed (S2 and FP7), Molteno (single-plate), and Baerveldt (250 and 350 mm²) GDIs were implanted onto cadaveric eyes with axial lengths ranging from 22.5 mm to 26.0 mm.⁶ The measured variable was the maximum distance that a GDI could be placed posterior to the limbus in the various quadrants without encroaching within 2 mm of the optic nerve. The location of the GDI relative to the various muscles was also examined. The average maximum distance from the limbus to the anterior plate edge ranged between 9.0 mm and 15.0 mm in the superotemporal (ST) quadrant for all GDI types tested.⁶

For the other 3 quadrants, the distances spanned 8.0 to 14.0 mm, 9.0 to 14.0 mm, and 11.0 to 17.0 mm for the superonasal (SN), inferonasal (IN), and inferotemporal (IT) quadrants, respectively.⁶ The "safe zone" from the plate to the optic nerve head was defined as 2 mm based on optic nerve changes found in rabbits after plates were implanted either abutting the optic nerve or within 1 mm of the nerve sheath.¹¹ Changes included microglial cell loss and localized astrocyte clustering.¹¹ Based on this study, the SN quadrant may offer the least amount of distance from the optic nerve for a GDI plate. This may be especially important for Ahmed GDIs, which have an anterior-posterior length of 16 mm compared with Molteno, Baerveldt 250 mm², and Baerveldt 350 mm² GDIs, having lengths of 13, 14, and 15 mm, respectively.⁶ The width of the plate is also an important factor to consider. The Baerveldt 250 mm² GDI has a width of 22 mm, whereas the Baerveldt 350 mm² GDI

has a width of 32 mm. The Ahmed, Molteno, and Krupin GDIs are 13 mm in width. The Baerveldt GDI plates, due to their wider plate widths, may be more likely to impinge on surrounding muscles, such as the rectus and oblique muscles. Such plate-muscle impingement may lead to patient discomfort and diplopia.

The IT quadrant is prone to more ocular muscle problems secondary to the close proximity of the inferior rectus and inferior oblique muscles. All GDIs, except for the Molteno, consistently contact the insertion site of the inferior oblique.⁶ If a ST quadrant placement is not ideal, the next best quadrant for GDI placement is the inferonasal quadrant. Despite a potentially more difficult insertion due to exposure issues, an IN plate insertion is less likely to interfere with the adjacent inferior oblique muscle, as suggested by comparison of inferonasal to IT placement of Baerveldt 350 mm² GDIs.¹² The variability of each patient's eye means that surgeons should be aware of the differences in the "safe" range for GDI placement from eye to eye and quadrant to quadrant. This is especially important in nanophthalmos and in small eyes in hyperopes and children.⁶

ADVANTAGES AND DISADVANTAGES OF TUBE AND PLATE LOCATIONS

Previous ocular surgery is an important factor when considering GDI placement. Quadrants that have had previous ocular surgery, especially trabeculectomy with antifibrotic therapy, may have thin, friable conjunctiva, which may make conjunctival closure over the plate difficult. If a superior trabeculectomy is present, a GDI placed inferonasally may be a good option. In cases of a previous scleral buckling procedure, the GDI plate can be placed above the fibrotic band of tissue without the need for dissecting away fibrous tissue to access extraocular muscles. A fibrous capsule forms around the plate without difficulty, and some glaucoma surgeons routinely place Baerveldt GDI plates over the muscle. Although the capsule profile may be slightly higher, patients typically have good cosmetic results, IOP control, and minimal risk of diplopia.

Our recommended site for placement of Molteno, Ahmed, or Baerveldt GDIs is the ST quadrant to avoid motility problems and for easier surgical access.¹ In cases of certain previous ocular surgery, such as trabeculectomy with antifibrotic agents or superior extracapsular cataract extraction (ECCE), the conjunctiva in the ST quadrant may be too scarred, thinned, or friable for placement of a superior GDI. In such cases, a GDI placed inferonasally may be appropriate (Figure 9-1). The IT quadrant is avoided for cosmetic reasons, as well as for the risk of diplopia or other motility problems associated with inferior oblique muscle dysfunction. Also, IN GDI placement may be preferable to a superior placement to avoid obstruction of

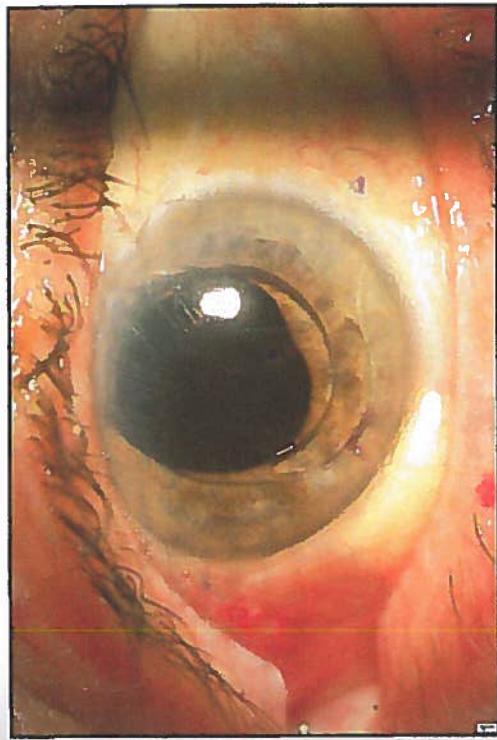


Figure 9-1. Inferonasal tube placement. This patient had a large superior extracapsular limbal wound from placement of an anterior chamber IOL. Note the 1 o'clock X-stitch that was part of the scleral wound closure which left the superior region with scarred conjunctiva. An inferonasal Baerveldt GDI was placed with a patch graft. The Baerveldt tube tip was placed right over the IOL haptic aimed away from the cornea.

the tube by silicone oil or egress of silicone oil into the subconjunctival space via the GDI, leading to significant inflammation.¹ The risk of hyphema (eg, in neovascular glaucoma) may preclude placing an inferior tube, as inferiorly layered blood may obstruct the filtering GDI tube tip, or the tube should be placed strategically longer for the tube tip to be higher within the anterior chamber.

The Ahmed S2 GDI has the highest profile at 1.9 mm and Baerveldt GDIs (both sizes) have the lowest profile at 0.84 mm.⁶ The size of the plate for the various GDIs is important not only for IOP-lowering considerations but also in terms of where the implant can and should be placed. Molteno introduced the idea of draining aqueous to a posterior plate away from the limbus in 1969.^{13,14} Although this led to decreased rates of exposure of the plate due to its posterior location, the risk of interference with extraocular muscles and even optic neuropathy from compression of the optic nerve increased. Similar to the Molteno GDI, the Ahmed GDI can be presumed to have similar plate characteristics in the various quadrants due to a similar plate profile and size (1.75 × 13 × 18 mm).⁵

The ST quadrant is the ideal plate location due to its combination of space, avoidance of the oblique muscles, and ease of exposure at the time of

surgery. If the ST quadrant is not accessible, the IN quadrant is the next best site based upon our clinical experience. The IT quadrant is not an ideal location due to the potential for inferior oblique impingement leading to ocular motility disturbance. Also, large bleb formation inferotemporally can lead to an undesired cosmetic result. Although superior and inferior Ahmed GDI placements have similar results in terms of IOP reduction and preservation of vision, Pakravan et al¹⁵ reported that inferiorly placed Ahmeds (which included a significant number placed inferotemporally) had more complications, including higher rates of wound dehiscence, tube or implant exposure, disfiguring encapsulation, lower lid bulge, exposure of the sclera patch graft, and endophthalmitis.

Anterior Chamber Tube Placement

Besides type of plate and plate placement location, the location of the GDI tube is also important. The GDI tube can be placed in different quadrants and different anterior-posterior chamber locations, such as anterior chamber (AC), sulcus, or pars plana (PP). AC tube placement is typically the most common location due to direct visualization and ease of placement during surgery. Postoperatively, the tube tip can be readily visualized to verify its placement and patency. Occlusion of the tube by iris, blood, fibrin, vitreous, and other ocular contents can be directly visualized for diagnosis and treatment of tube occlusion. An AC tube is also amenable for ripcord suture removal for early tube opening in the clinic. Also, if tube retraction is a concern, gonioscopy can be performed to verify the tube is in the AC. Some disadvantages to AC tube placement include corneal damage if the tube is in contact with the corneal endothelium, which can result in endothelial cell loss, corneal edema, and possible need for keratoplasty.¹⁶ Eye rubbing can also cause areas of focal corneal edema due to intermittent tube-cornea contact. Another disadvantage is the difficulty of placing a tube in the AC in a quadrant where pre-existing high peripheral anterior synechia (PAS) is present.

The ST quadrant is ideal for AC placement of the tube, partly because it is the most spacious quadrant for plate placement and surgical site access during surgery. The tube is also easy to visualize with inferior gaze for laser suture lysis (LSL) through a corneal patch graft if early tube opening is necessary. For issues regarding patency of the tube or whether the GDI is filtering properly, the ST quadrant is relatively simple for ultrasound to visualize fluid over the plate and, at the slit lamp, a view of plate edge for the presence of a filtering bleb is relatively simple compared with other quadrants. A disadvantage of the ST location is that eye rubbing can more easily cause extrusion of the tube or erosion of the conjunctiva overlying the tube, especially in the early postoperative course. The risk of tube erosion can be

minimized by routing the tube to enter the AC more superiorly toward the 12 o'clock meridian, which places the tube and patch graft entirely underneath the upper lid.¹⁶

If the ST quadrant is unavailable for GDI placement secondary to previous trabeculectomy, superior ECCE wound, or other reason for scarred or friable superior conjunctiva, the IN quadrant is our preferred next option for AC tube insertion. Adequate space exists inferonasally for most GDI plates and oblique muscles are avoided for a lower risk of diplopia. Tube erosion or extrusion is also less likely in the IN quadrant. If silicone oil is in the eye or may be needed in the future, the IN quadrant location of the tube minimizes the risk of silicone oil obstructing the tube. Some disadvantages of an IN tube include poorer cosmesis (the upper lid usually helps hide the tube in the ST AC), and hyphema can occlude an inferior tube tip if not above the level of the hyphema. For IN tubes, we typically use a transparent corneal patch graft to minimize cosmesis issues. → KEP-AS-15 OR CORNEA

Placement of a tube in the AC in the SN and IT quadrants is often not ideal because of more difficult surgical site access for plate implantation, risk of diplopia, and cosmesis. Even implanting the plate in the ST or IN quadrants and routing the tube to the SN and IT quadrants is not ideal and may require use of a tube extender for optimal tube placement. The IT quadrant location is difficult due to possible interference with inferior oblique muscle function, hyphema obstructing the tube, and poorer cosmetic results with increased patch graft show.

Posterior Chamber Tube Placement

In eyes with a disorganized anterior segment, current or future need for keratoplasty, neovascularization of the angle, significant and/or high peripheral anterior synechia, a shallow anterior chamber, history of PP vitrectomy, or future need for vitrectomy, a posterior chamber placement of a tube may be ideal.¹⁷ A tube placed in the PP probably has a lower risk of erosion by virtue of the tube location being more posterior from the limbus and covered by Tenon's and other soft tissue.¹⁶ If a tube is placed in the PP, a complete vitrectomy to the vitreous skirt or base needs to be performed to prevent tube tip blockage by residual vitreous.¹⁸ If blocked by vitreous, PP tube placement makes visualization of the tube tip difficult, and lasering the tube tip or needling the tube tip to remove the obstruction is typically not an option. A PP tube is also associated with a risk of retinal detachment, especially if significant inflammation occurs upon opening of a nonvalved tube with ligature release. Other contraindications of a PP tube include abnormalities of the sclera and lens status of the eye.¹⁸ A higher postoperative hypotony risk was observed when a GDI tube was placed through a sclerostomy as opposed to AC placement.¹⁸ When placing a tube in the PP

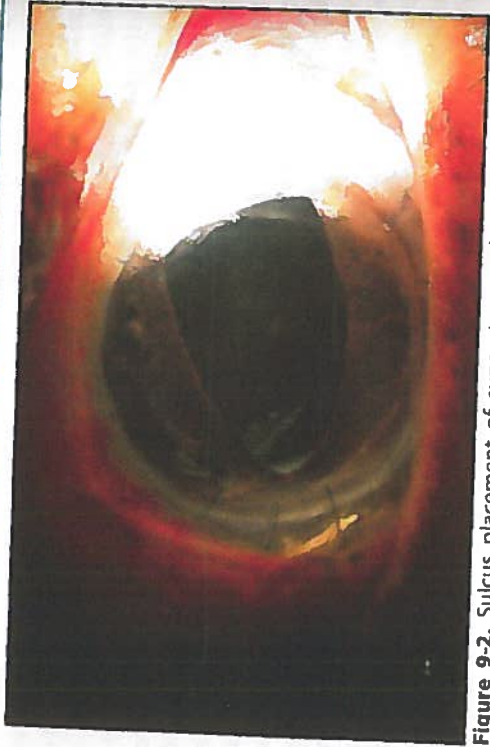


Figure 9-2. Sulcus placement of superotemporal GDI tube. This pseudophakic patient with a history of a penetrating keratoplasty had a superotemporal GDI placed for chronic angle-closure glaucoma. Secondary to high PAS associated with the history of corneal transplantation, the tube was placed in the sulcus, which kept it away from the cornea and above the IOL, minimizing the risk of vitreous tube occlusion and allowing for easy insertion of the tube.

(unless employing the Hoffman elbow for tube insertion), use of a 20-gauge microvitrectomy blade creates a larger opening compared with a 23-gauge needle, and the resulting leakage around the sclerostomy site can lead to postoperative hypotony.

Sulcus placement of a tube may be an ideal compromise between an AC and a PP tube location in pseudophakic eyes. When a tube is placed in the sulcus, the tube is posterior to the iris, which keeps the tip below the iris plane and prevents tube contact with the cornea. This should prevent any direct corneal endothelial loss associated with tube corneal contact. A sulcus placement is also away from the vitreous and above the IOL, which typically prevents vitreous obstruction of the tube, especially with the tip bevel turned toward the IOL to minimize iris incarceration. Placing a tube in the sulcus may be more technically challenging. Ideal eyes for a sulcus tube placement are nonvitrectomy pseudophakic eyes with high PAS, such as neovascular or chronic angle-closure eyes (Figure 9-2).

Tube Entry Location

In certain cases, the length of the tube in a GDI may be inadequate after placement and may need to be relocated to a different position. This may occur in pediatric patients, in whom axial growth can lead to tube

retraction from the globe.¹⁹ Acute trauma, malposition of the tube, tube tip occlusion, accidentally shortened tubes (eg, cutting in the operating room), and eye-rubbing-associated tube extrusion may require that the tube location be changed.²⁰ Various methods for relocating a tube exist, including using a connecting segment of 22-gauge angiocatheter tubing,²¹ a silastic sleeve,²² a small-diameter silastic tube connected to the original tube,²³ or a commercially available tube extender, such as the Model TE (New World Medical, Inc).²⁰ A tube extender allows the surgeon to reroute a tube away from areas of high PAS or reoperated or scarred conjunctiva without having to explant an existing GDI and place a new GDI in a separate location for IOP control. Relocating an extruded tube is a relatively straightforward method to preserve a filtering GDI.

KEY POINTS

1. Our preference for GDI placement location is in the superotemporal quadrant, and in the inferonasal quadrant as the second choice for reasons including ease of surgical access, improved cosmesis, decreased risk of diplopia, access for laser suture lysis in nonvalved GDIs, and decreased risk of optic nerve damage.
2. A larger glaucoma drainage plate size improves IOP control, but only to a certain point (ie, bigger is not always better and may increase the risks of complications such as diplopia).
3. Anterior chamber GDI tube placement is preferred because visualization of the tube tip can aid in the diagnosis of poor or blocked filtration secondary to iris incarceration, fibrin, and other occlusions that are amenable to manipulation, such as laser treatment.
4. Posterior chamber GDI tube placement is preferred in cases of a shallow anterior chamber; other corneal problems (eg, Fuchs' dystrophy, penetrating keratoplasty, or iridocorneal endothelial syndromes), or anterior segment problems that are planned for a vitrectomy. Sulcus GDI tube placement is often ideal for pseudophakic eyes with high PAS.

REFERENCES

1. Dietlein TS, Jordan J, Lueke C, Kriegelstein GK. Modern concepts in antiglaucomatous implant surgery. *Graefes Arch Clin Exp Ophthalmol*. 2008;246(12):1653-1664.
2. Minckler DS, Vedula SS, Li TJ, et al. Aqueous shunts for glaucoma. *Cochrane Database Syst Rev*. 2006(2):CD004918.
3. Gedde SJ, Schiffman JC, Feuer WJ, et al. Treatment outcomes in the tube versus trabeculectomy study after one year of follow-up. *Am J Ophthalmol*. 2007;143(1):9-22.
4. Schwartz KS, Lee RK, Gedde SJ. Glaucoma drainage implants: a critical comparison of types. *Curr Opin Ophthalmol*. 2006;17(2):181-189.

5. Krupin eye valve with disk for filtration surgery. The Krupin Eye Valve Filtering Surgery Study Group. *Ophthalmology*. 1994;101(4):651-658.
6. Kahook MY, Noecker RJ, Panticheva MB, Schuman JS. Location of glaucoma drainage devices relative to the optic nerve. *Br J Ophthalmol*. 2006;90(8):1010-1013.
7. Lloyd MA, Baerveldt G, Fellenbaum PS, et al. Intermediate-term results of a randomized clinical trial of the 350- versus the 500-mm² Baerveldt implant. *Ophthalmology*. 1994;101(8):1456-1463.
8. Heuer DK, Lloyd MA, Abrams DA, et al. Which is better? One or two? A randomized clinical trial of single-plate versus double-plate Molteno implantation for glaucomas in aphakia and pseudophakia. *Ophthalmology*. 1992;99(10):1512-1519.
9. Ishida K, Netland PA, Costa VP, et al. Comparison of polypropylene and silicone Ahmed Glaucoma valves. *Ophthalmology*. 2006;113(8):1320-1326.
10. Nouri-Mahdavi K, Caprioli J. Evaluation of the hypertensive phase after insertion of the Ahmed Glaucoma Valve. *Am J Ophthalmol*. 2003;136(6):1001-1008.
11. Ayyala RS, Parma SE, Karcioglu ZA. Optic nerve changes following posterior insertion of glaucoma drainage device in rabbit model. *J Glaucoma*. 2004;13(2):145-148.
12. Sidoti PA. Inferonasal placement of aqueous shunts. *J Glaucoma*. 2004;13(6):520-523.
13. Molteno AC. New implant for drainage in glaucoma. Clinical trial. *Br J Ophthalmol*. 1969;53(9):606-615.
14. Molteno AC. New implant for drainage in glaucoma. Animal trial. *Br J Ophthalmol*. 1969;53(3):161-168.
15. Pakravan M, Yazdani S, Shahabi C, Yaseri M. Superior versus inferior Ahmed glaucoma valve implantation. *Ophthalmology*. 2009;116(2):208-213.
16. Heuer DK, Budenz D, Coleman A. Aqueous shunt tube erosion. *J Glaucoma*. 2001;10(6):493-496.
17. de Guzman MH, Valencia A, Farinelli AC. Pars plana insertion of glaucoma drainage devices for refractory glaucoma. *Clin Experiment Ophthalmol*. 2006;34(2):102-107.
18. Scott IU, Alexandrakis G, Flynn HW Jr, et al. Combined pars plana vitrectomy and glaucoma drainage implant placement for refractory glaucoma. *Am J Ophthalmol*. 2000;129(3):334-341.
19. Dawodu O, Levin AV. Spontaneous disconnection of glaucoma tube shunt extenders. *J AAPOS*. 2010;14(4):361-363.
20. Sarkisian SR, Netland PA. Tube extender for revision of glaucoma drainage implants. *J Glaucoma*. 2007;16(7):637-639.
21. Smith MF, Doyle JW. Results of another modality for extending glaucoma drainage tubes. *J Glaucoma*. 1999;8(5):310-314.
22. Kooner KS. Repair of Molteno implant during surgery. *Am J Ophthalmol*. 1994;117(5):673.
23. Minckler D. Pathophysiology, indications, and surgical technique: glaucoma drainage devices. In: Weinreb RN, Mills RP, eds. *Glaucoma Surgery: Principles and Techniques*. San Francisco, CA: American Academy of Ophthalmology; 1998.

USE OF ANTIMETABOLITES WITH TUBE SHUNT SURGERY

Anup K. Khatana, MD

Glaucoma surgeons struggle with the adverse effects of scarring on a daily basis. Tube shunts were able to increase the success rate of filtration surgery in certain complex glaucomas and eyes that had either failed or were unable to undergo a trabeculectomy. However, they were still limited to varying degrees by the nature of the fibrotic capsule that formed over the distal plate of the shunt. The ability of 5-fluorouracil (5-FU) and mitomycin C (MMC) to increase the success rate of trabeculectomy stirred interest among glaucoma surgeons to investigate their effects with tube shunts.

TUBE VERSUS TRABECULECTOMY

Before we assess the potential role for antimetabolite use in glaucoma implant surgery, it is helpful to look at how implants without antimetabolites compare with standard trabeculectomy with mitomycin C. In 2009, the 3-year follow-up results were published for the Tube Versus Trabeculectomy (TVT) Study. This study was a multicenter US trial that included open-angle glaucoma patients with previous trabeculectomy or cataract extraction with intraocular lens (IOL) implantation, or both, and uncontrolled glaucoma with intraocular pressure (IOP) between 18 and 40 mm Hg, inclusive. Patients were randomized to undergo either a 350-mm² Baerveldt glaucoma implant or trabeculectomy with MMC. Of the 212 patients enrolled, the mean IOP at 3 years was 13.0±4.9 mm Hg on 1.3±1.3 glaucoma medications in the tube group, and 13.3±6.8 mm Hg on 1.0±1.5 glaucoma medications in the trabeculectomy group. Interestingly, the cumulative probability of failure was 15.1% in the tube group and 30.7% in the trabeculectomy group during this 3-year follow-up. It was also interesting to note that 39% of patients in the tube group and 60% in the trabeculectomy group developed some postoperative complication, although most were transient and self-limited! As we discuss

the role for antimetabolites in tube shunt surgery, the results of the TVT trial demonstrate the effectiveness of the Baerveldt glaucoma implant in controlling pressure without the use of antimetabolites. The question remains as to whether we can safely augment the IOP reduction from tube shunt surgery with antimetabolites in a manner similar to that seen with trabeculectomy.

EARLY ANIMAL STUDIES

The first published report of the use of MMC with a tube shunt was in 1993 by Choi and colleagues, using an anterior chamber silicone tube to an expanded polytetrafluoroethylene membrane in rabbit eyes. Histologically, the capsules that formed over the membrane in the MMC group were less cellular and less dense, with less proliferating fibrous connective tissue and more microcystic spaces, suggesting higher permeability to aqueous humor.² Another rabbit study done by Prata, Minckler and colleagues investigated the use of 0.5 mg/mL MMC for 5 minutes with Baerveldt glaucoma implants followed for 24 weeks postoperatively. No postoperative steroids were used. The MMC eyes had thinner and less cellular capsules with less dense collagen layers over the implant compared to the controls. The IOP was lower in the MMC-treated eyes at all time points, but the difference was only statistically significant up to 8 weeks postoperatively. The control eyes demonstrated a "hypertensive phase" that peaked at 4 weeks, but a gradual rise in IOP until 6 weeks followed by a gradual decline through the 11th week. The MMC-treated group demonstrated a minimal "hypertensive phase" with only a small rise in IOP by 6 weeks. Resistance to flow was lower in the MMC-treated group at all time points, but this difference was only statistically significant through 6 weeks postoperatively. Flow rates through the implant bleb were also higher at all time points in the MMC-treated group, and were statistically significant at 2, 4, 6, and 24 weeks postoperatively. The complication rate was also higher, with wound dehiscence, bleb leaks, and extraocular muscle hemorrhagic necrosis observed only in some of the MMC-treated eyes, but none of the controls.³ It is important to keep in mind that the extraocular muscle capsule has been noted to be thinner in rabbits than humans. This may help explain the higher rate of related complications in the MMC group.

HUMAN CLINICAL STUDIES

There have been a number of publications on the use of MMC with tube shunts in humans. Some have been prospective and randomized, while others have been observational retrospective case series. These studies vary in the type of implant used, MMC application, length of follow-up, definitions of success, etc. Two early studies by Susanna et al⁴ and Perkins et al⁵ compared MMC in the implantation of Molteno implants to historical

controls where no MMC was used. These studies suggested a beneficial effect of MMC. Cantor et al⁶ prospectively randomized patients undergoing double-plate Molteno implantation to either MMC 0.4 mg/mL for 2 minutes or a balanced salt solution control. Costa et al⁷ prospectively randomized patients undergoing Ahmed glaucoma valve implantation to an intraoperative application of either MMC 0.5 mg/mL for 5 minutes or balanced salt solution. Neither of these studies found a statistically significant difference between the MMC and control groups in IOP, number of anti-glaucoma medications, or complications. Three retrospective studies that used a historical control group also found no evidence of higher surgical success with adjunctive MMC in single-plate Molteno, Baerveldt 350 mm², and Ahmed valve tube shunts, respectively.⁸⁻¹⁰

In another retrospective comparative series in a pediatric population, Al-Mobarak and Khan¹¹ found a shorter survival at 2 years' follow-up with Ahmed valves implanted with intraoperative MMC than those without MMC in children during the first 2 years of life (mean age at implantation: 11.1 months). Pakravan et al¹² found comparable outcomes between trabeculectomy with MMC versus Ahmed valve with MMC for the treatment of aphakic glaucoma in children under the age of 16.

The classic hypertensive phase after tube shunt surgery is a period of IOP elevation that begins typically approximately 5 weeks postoperatively from the formation of a bleb capsule over the plate of the shunt and can last up to 6 months postoperatively. It is presumed to be due to the lower permeability of the initial capsule that forms over the plate of the shunt. Through wound remodeling, the permeability of the capsule slowly increases, resulting in a gradual decline in IOP. Ellingham et al¹³ showed that MMC (0.3 mg/mL for 3 minutes) applied to Tenon's capsule over the secondary plate of double-plate Molteno implants was able to blunt the hypertensive phase. However, no significant difference was seen with the use of MMC on the hypertensive phase in the Cantor study.⁶ Part of the rise in IOP that occurs approximately 3 to 4 weeks postoperatively in nonvalved shunts that are ligated and receive venting slits is due to fibrosis around the tube in the area of the venting slits. Tribble and Brown¹⁴ investigated the effect of 5-FU and MMC applied locally only to the sclera in the area of a standardized venting slit (but not directly to the area over the plate where the bleb would form) after the plate was secured to the sclera. There was no statistically significant difference between the 5-FU and MMC groups. Susanna¹⁵ studied the effect of adjunctive MMC in Ahmed glaucoma valve surgery with or without partial Tenon's capsule resection. They found no benefit or no increase in complications from partial Tenon's capsule resection.

MMC has also been studied and used with tube shunt revisions. Zarei and Shahhosseini¹⁶ found limited benefit to needing bleb revision with

MMC for failed Molteno tubes. The success rate was 87.5% at 3 months, 37.5% at 6 months, and 12.5% at 24-months follow-up. The reader is also referred to an excellent Cochrane review analyzing all of the published literature on aqueous shunts in glaucoma by Minckler et al¹⁷ in 2006.

LABORATORY STUDIES

Freedman and Goddard¹⁸ studied aqueous humor samples obtained from eyes that underwent Molteno implants, trabeculectomy, and cataract surgery. They found that transforming growth factor beta (TGF- β) and prostaglandin E2 (PGE2) levels were higher in the Molteno and trabeculectomy eyes than in cataract surgery eyes. There was also a trend toward higher levels of PGE2 and TGF- β in patients with a higher IOP. They postulated that a sustained IOP rise, such as that seen with encapsulated blebs and during the hypertensive phase, stimulates production of PGE2 and TGF- β . These factors mediate ongoing inflammation, progressive fibrosis, and a sustained rise in IOP.

Occleston et al¹⁹ showed that one 5-minute in vitro exposure of 5-FU or MMC significantly inhibited cultured human Tenon's capsule fibroblast migration and decreased growth factor production, growth factor receptor expression, and extracellular matrix production initially. The effects were greater with MMC than 5-FU as expected. However, these values gradually returned to control levels starting approximately 1 week after the exposure and reached control levels approximately 5 weeks after the exposure. In addition, even the growth-arrested cells appeared to be capable of producing growth factors, expressing growth factor receptors, and producing extracellular matrix. This may perhaps explain the inability of antimetabolites to completely prevent failure from fibrosis in all glaucoma surgeries.

PERSONAL EXPERIENCE

I first began to use MMC with tube shunts in 2002, based on the goal of trying to achieve lower IOPs and reduce the need for adjunctive medical therapy. Minimizing topical therapy is particularly important when managing glaucoma in eyes with complex ocular surface disease, such as those that have undergone limbal stem cell transplantation. It was felt that the potential inflammatory effects of IOP-lowering eye drops could adversely affect the limbal stem cell transplants.

I have not observed any higher incidence of complications since beginning to use MMC, nor do my complication rates seem higher than published reports. Although I have not performed a comparative trial, it is my impression that MMC does help achieve lower IOPs and may also reduce

the dependence on medications to achieve IOP control. It is also my clinical impression that MMC helps to blunt the hypertensive phase.

When one begins to use an agent like MMC, it is advised to use the standard concentration that one is already familiar with when performing trabeculectomies. I recommend starting with a relatively short duration of 30 to 60 seconds. Observe the clinical course of these patients and then gradually adjust the exposure as needed. MMC has been accepted to increase the success rate of trabeculectomies and has been widely adopted in that setting. Animal studies with MMC and tube shunts have also suggested a (mostly) beneficial effect on the exposed tissue. However, it is curious that the majority of the clinical studies have not shown any significant long-term benefit from adjunctive MMC with tube shunts. The answer may well be multifactorial. The Occleston study,¹⁹ showing that growth-arrested cells still produce growth factors, may shed light on at least part of the cause. It is also possible that an inadequate dose of MMC has been used.

KEY POINTS

1. The 3-year results of the TVT study showed comparable results between Baerveldt 350 tube shunts without MMC and trabeculectomy with MMC.
2. Adjunctive use of MMC during tube shunt implantation in rabbit eyes created less dense and less cellular fibrous capsules over the implant plate, and less resistance to outflow compared to controls.
3. Human clinical studies have shown mixed results, but the majority of them have not shown any long-term benefit from MMC. One study did show a positive effect on the hypertensive phase from MMC use.
4. Some evidence suggests a correlation between elevated levels of TGF- β and PGE2 in eyes that have an elevated IOP after tube shunt surgery.
5. In vitro evidence indicates incomplete inhibition of fibroblasts from a single exposure of 5-FU or MMC and a gradual loss of the physiologic effects on the fibroblasts over 1 to 5 weeks after the exposure.

REFERENCES

1. Gedde SJ, Schiffman JC, Feuer WJ, Herndon LW, Brandt JD, Budenz DL. Three-year follow-up of the tube versus trabeculectomy study. *Am J Ophthalmol.* 2009;148(5):670-684.
2. Choi WS, Park SJ, Kim DM. Mitomycin C in anterior chamber tube shunt to a surgical membrane. *Korean J Ophthalmol.* 1993;7(2):48-54.
3. Prata JA, Minckler DS, Mermoud A, Baerveldt G. Effects of intraoperative mitomycin C on the function of Baerveldt glaucoma drainage implants in rabbits. *J Glaucoma.* 1996;5(1):29-38.
4. Susanna R Jr, Nicoletta MT, Takahashi WY. Mitomycin C as adjunctive therapy with glaucoma implant surgery. *Ophthalmic Surg.* 1994;25(7):458-462.

5. Perkins TW, Cardakli UF, Eisele JR, Kaufman PL, Heatley GA. Adjunctive mitomycin C in Molteno implant surgery. *Ophthalmology*. 1995;102(1):91-97.
6. Cantor L, Burgoyne J, Sanders S, Bhavnani V, Hoop J, Brizendine E. The effect of mitomycin C on Molteno implant surgery: a 1-year randomized, masked, prospective study. *J Glaucoma*. 1998;7(4):240-246.
7. Costa VP, Azuara-Blanco A, Netland PA, Lesk MR, Arcieri ES. Efficacy and safety of adjunctive mitomycin C during Ahmed Glaucoma Valve implantation: a prospective randomized clinical trial. *Ophthalmology*. 2004;111(6):1071-1076.
8. Lee D, Shin DH, Birt CM, et al. The effect of adjunctive mitomycin C in Molteno implant surgery. *Ophthalmology*. 1997;104(12):2126-2135.
9. Irak I, Moster MR, Fontanarosa J. Intermediate-term results of Baerveldt tube shunt surgery with mitomycin C use. *Ophthalmic Surg Lasers Imaging*. 2004;35(3):189-196.
10. Kurnaz E, Kubaloglu A, Yilmaz Y, Koytak A, Ozerturk Y. The effect of adjunctive Mitomycin C in Ahmed glaucoma valve implantation. *Eur J Ophthalmol*. 2005;15(1):27-31.
11. Al-Mobarak F, Khan AO. Two-year survival of Ahmed valve implantation in the first 2 years of life with and without intraoperative mitomycin-C. *Ophthalmology*. 2009;116(10):1862-1865.
12. Pakravan M, Homayoon N, Shahin Y, Ali Reza BR. Trabeculectomy with mitomycin C versus Ahmed glaucoma implant with mitomycin C for treatment of pediatric aphakic glaucoma. *J Glaucoma*. 2007;16(7):631-636.
13. Ellingham RB, Morgan WH, Westlake W, House PH. Mitomycin C eliminates the short-term intraocular pressure rise found following Molteno tube implantation. *Clin Experiment Ophthalmol*. 2003;31(3):191-198.
14. Tribble JR, Brown DB. Occlusive ligature and standardized fenestration of a Baerveldt tube with and without antimetabolites for early postoperative intraocular pressure control. *Ophthalmology*. 1998;105(12):2243-2250.
15. Susanna R Jr; Latin American Glaucoma Society Investigators. Partial Tenon's capsule resection with adjunctive mitomycin C in Ahmed glaucoma valve implant surgery. *Br J Ophthalmol*. 2003;87(8):994-998.
16. Zarei R, Shalhosseini S. Needling revision with mitomycin C for failed Molteno tube shunt implant. *Asian J Ophthalmol*. 2007;9:27-29.
17. Minckler DS, Vedula SS, Li TJ, Mathew MC, Ayyala RS, Francis BA. Aqueous shunts for glaucoma. *Cochrane Database Syst Rev*. 2006;19(2):CD004918.
18. Freedman J, Goddard D. Elevated levels of transforming growth factor beta and prostaglandin E2 in aqueous humor from patients undergoing filtration surgery for glaucoma. *Can J Ophthalmol*. 2008;43(3):370.
19. Occleston NL, Daniels JT, Tarnuzzer RW, et al. Single exposures to antiproliferatives. Long-term effects on ocular fibroblast wound-healing behavior. *Invest Ophthalmol Vis Sci*. 1997;38:1998-2007.

CONSIDERATIONS ON DAY OF GLAUCOMA DRAINAGE IMPLANT SURGERY

Jeffrey M. Zink, MD

On the day of aqueous drainage implant surgery, there are some important things to consider to help achieve desired results. Although it is necessary to plan in advance prior to surgery, there are some important considerations on the actual day of surgery as well. Attention to detail regarding preparations in the holding area, preoperative equipment check, anesthesia type, operative positioning for surgeon and patient, last-minute implant considerations, and intraoperative tissue and anatomical assessments can help to achieve more optimal results.

HOLDING AREA

The holding area is where you want to make sure that the patient understands the surgery and that you answer any last-minute questions or concerns. The surgeon must make sure the patient has signed the consent form for the appropriate tube shunt surgery and that the correct eye is scheduled. Mark the patient's operative eye in the holding area and confirm the correct eye with the patient. Review the surgical consent form and ensure that placement of a tissue patch graft is included in the surgical consent form. Ensure that the patient is willing to accept donor tissue, as most patients do not consider glaucoma surgery as involving transplanted tissue. Some patients will not accept transplanted tissue for religious reasons, and it is important to have this conversation and make them aware that transplanted patch graft material is part of this type of glaucoma surgery. If the patient is on warfarin, I like to check an international normalized ratio blood test on the day of surgery. If the patient is taking clopidogrel or other blood thinners, ask when these medications were discontinued. If blood thinners were

not stopped, you may want to consider topical or intraoperative sub-Tenon's anesthesia.

PREOPERATIVE CHECK

It is important to make sure you have the correct implant available prior to the surgery. I like to have a second implant of similar type available in case one is defective or if the device is damaged during surgery. I also recommend having a tube extender available, especially in training programs. If the tube is inadvertently cut too short, a tube extender will allow the tube to be extended and placed at the desired length in the anterior chamber. Make sure that the donor patch graft material is present and stored appropriately. If there is the possibility of placing an inferior tube, I prefer to have corneal patch graft available for cosmetic reasons. Corneal patch material is clear and does not show up on the sclera as conspicuously as scleral patch grafts when placed inferiorly. For cosmesis, processed pericardium is preferable to sclera but less preferable than cornea. If patch graft tissue is ordered from an eye bank, make sure to check the eye bank paperwork to ensure that all proper serologic testing has been done and the appropriate titers are negative.

ANESTHESIA

Anesthesia for glaucoma drainage implant surgery can vary from topical with subconjunctival supplementation, peribulbar block, or retrobulbar block. The type of anesthesia that is needed should be tailored to the level of complexity of the case in terms of tissue manipulation and the patient's ability to cooperate during the surgical procedure. I prefer intraoperative sub-Tenon's anesthesia or a peribulbar block in the holding area. I use a long block consisting of a 50:50 mixture of 0.5% marcaine and 2% lidocaine. In complex cases that require extensive tissue dissection and manipulation, a standard retrobulbar block may be required.

POSITIONING

The importance of proper patient and surgeon positioning in the operating room cannot be overstated. Make sure your patient is comfortable and you have adjusted the head positioning so that it minimizes neck and back discomfort during the surgery. If your patient is not comfortable, they are more likely to move suddenly. Consider taping the patient's head to minimize the risk of sudden movement. Some surgeons prefer to use a wrist rest to stabilize their hands during surgery. I like to sit superiorly during aqueous drainage implant surgery. Some surgeons prefer to sit slightly offset

from 12 o'clock to the side of implant placement location to give them better access to the superior temporal quadrant.

IMPLANT CONSIDERATIONS

Intraoperative examination is important when determining implant location. If patients have a very tight orbital space, you may favor implanting a smaller plate tube shunt. Sometimes, you may not be able to determine the appropriate size of the implant until you have started the dissection and better evaluate orbital anatomy in the operating room. In patients with a prior scleral buckling procedure, I prefer a lower profile tube shunt, such as a Baerveldt 250 mm² implant, which can be sewn to the buckle itself or just posterior to the buckle, depending on the buckle location.

Normally, the preferred location of implant placement is the superior temporal quadrant. Intraoperatively, you may notice extensive conjunctival scarring superiorly in some cases. The conjunctiva may also be very thin and friable from previous trabeculectomy surgery and mitomycin C (MMC) exposure. In these cases, the inferior nasal quadrant can be a great alternative location for implant placement. If you think that inferior tube shunt placement may be necessary, it is a good idea to have corneal tissue available for patch material, as previously mentioned, to provide a less conspicuous patch graft. A scleral patch graft can be quiet visible when placed inferiorly. In addition, I prefer a tube that achieves a lower profile, such as the Baerveldt 250 mm² or 350 mm² for inferior tube placement. Although Ahmed implants can be placed in the inferior nasal quadrant, I have found that an implant with a lower profile is a better alternative cosmetically.

CONJUNCTIVAL CLOSURE CONSIDERATIONS

In general, with healthy conjunctival tissue, I prefer closure with an 8-0 braided Vicryl suture on a TG-140 needle. For very friable tissue, or tissue with previous MMC exposure, a 9-0 monofilament Vicryl suture on a VAS-100 needle works well. Monofilament Vicryl can be used in routine cases, but it costs more than braided Vicryl and is usually not necessary.

KEY POINTS

1. Attention to detail and being prepared on the day of surgery is important to be able to provide optimal patient care.
2. If considering inferior glaucoma drainage implant placement, consider having corneal patch tissue and a lower-profile implant, such as a Baerveldt, available to achieve more desirable cosmetic results.

SUGGESTED READINGS

- Minckler DS, Vedula SS, Li TJ, Mathew MC, Ayyala RS, Francis BA. Aqueous shunts for glaucoma. *Cochrane Database Syst Rev*. 2006;(2):CD0004918.
- Patel S, Pasquale LR. Glaucoma drainage devices: a review of the past, present, and future. *Semin Ophthalmol*. 2010;25(5-6):265-270.
- Sidoti PA, Baerveldt G. Glaucoma drainage implants. *Curr Opin Ophthalmol*. 1994;5(2):85-98.

12

POSTOPERATIVE MANAGEMENT OF GLAUCOMA DRAINAGE IMPLANTS

Jeffrey M. Zink, MD

The postoperative management of glaucoma drainage implants is important in determining the success of the surgery. Patient education, medications, and in-office procedures are important things to consider when managing the postoperative glaucoma drainage implant patient.

PATIENT EDUCATION

The first part of successful glaucoma surgery is patient education. It is important to spend time educating your patients about what to expect, proper eye drop usage and compliance following surgery. Proper eye drop use is critical for postoperative intraocular pressure (IOP) control, inflammation treatment, and infection prophylaxis. Many glaucoma drainage implant patients may have medical conditions that make drop instillation difficult, such as dementia, arthritis, tremor, or coordination issues. In these patients, I find it helpful to elicit the aid of a reliable family member of the patient to assist with postoperative drop instillation. I like to provide a detailed sheet with drop instructions for the patient to take home following surgery. It is important to include bottle top colors and use large font to facilitate the reading and understanding of drop instructions. Giving patients a written schedule to follow, in a form they can understand and read, will improve compliance with complicated postoperative drop schedules.

As with any other intraocular surgery, it is important to tell patients to call if they notice worsening redness, pain, sudden loss of vision, discharge, or swelling. Most patients are very concerned about the appearance and comfort of their eye following tube shunt surgery. Foreign body sensation from sutures, moderate conjunctival injection, and subconjunctival hemorrhages are commonly seen following surgery. It is important to have patients look at their eye on the first postoperative day, so they know if the appearance of the

eye changes for the worse. Educating patients on what to be concerned about and when to call their surgeon is an important first step in managing and avoiding problems following glaucoma drainage implant surgery.

MEDICATIONS

A typical postoperative drop regimen for tube shunt surgery includes prednisolone acetate 1% 4 times a day and an antibiotic drop 4 times a day for the first week after surgery. If a patient is a known steroid responder, one can substitute loteprednol etabonate instead of prednisolone acetate. I prefer a fluroquinolone antibiotic for 1 week following surgery. I prefer a longer antibiotic course for some conditions, such as wound leaks, surface disease requiring contact lens use, or moderate to severe blepharitis. Higher doses of steroids may be necessary in patients with known uveitis or a predisposition to intraocular inflammation. Cycloplegics should be used when hypotony, shallow chamber, and choroidal effusions are present to facilitate anterior chamber deepening. Steroids and cycloplegics will help reduce the risk of peripheral anterior synechiae formation in the setting of hypotony.

VALVED IMPLANTS

Typically, the steroids can be slowly tapered in the case of valved implants over the course of the first month or 2. They may need to be continued longer if a hypertensive phase develops. For further details on the hypertensive phase, please see Chapter 13.

When a valved glaucoma drainage implant is placed, flow is immediately established between the anterior chamber and the subconjunctival space over the implant, assuming that the valve is functioning and has been primed appropriately. This creates a higher likelihood of a low IOP in the immediate postoperative period for valved implants. These patients may need to be followed more closely during the early postoperative period for shallow chambers, hypotony, and choroidal effusions. Rarely, it may be necessary to reform the anterior chamber with viscoelastic if there is profound hypotony with a flat chamber in the early postoperative period (the reader is referred to the next section for further details on viscoelastic injections). In most cases, the early hypotony seen on valved implants can be managed with cycloplegics, steroids, and close monitoring. When hypotony is present, it is important to tell patients to avoid lifting, bending, or straining. I prefer to have them keep their head elevated on a pillow when sleeping and wear a protective shield at night. Typically, when there is hypotony following the implantation of a valved implant, it resolves in the first week or 2 with conservative treatment. Some surgeons advocate performing suture ligation of valved implants, such as the Ahmed, to avoid the risk of early postoperative hypotony.

NONVALVED IMPLANTS

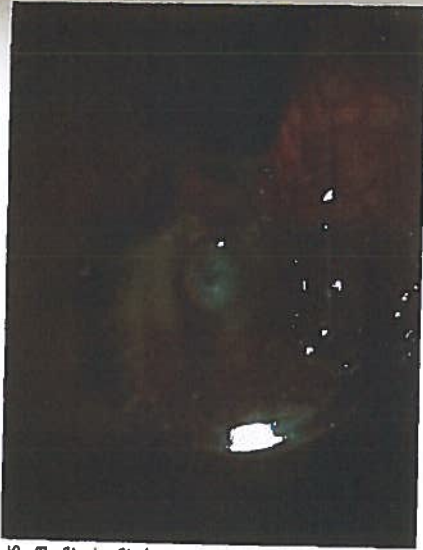Management Prior to Tube Opening

In a typical nonvalved implant, such as a Baerveldt or Molteno, there is a higher likelihood that you may be dealing with higher pressures in the immediate postoperative period due to the tube ligation and stent suture. These patients often need to restart their glaucoma drops and sometimes require oral carbonic anhydrase inhibitors following surgery until the tube opens. Initially, I like to start with aqueous suppressants. In general, I avoid prostaglandin analogues unless absolutely necessary out of concern for augmenting postoperative inflammation.

Because the nonvalved aqueous drainage implant is ligated in most cases in the early postoperative period, sometimes there is a need to lower IOP beyond what medicines can provide. In the very early postoperative period, one can use a TG-140 needle to fenestrate the tube proximal to the tube ligation site to allow egress of fluid through the fenestration. This can be done as a simple in-office procedure at the slit lamp. A betadine drop, antibiotic, and 2% lidocaine gel are placed in the eye. A temporal lid speculum is placed and a locking needle driver with a TG-140 needle is used to enter to subconjunctival space adjacent to the tube. The tube is then visualized anterior to the ligature suture and the needle is used to put a fenestration in the tube. The surgeon needs to take great care during this procedure to avoid violating the sclera and avoid globe perforation. The needle is then removed from the subconjunctival space after a fluid wave is observed. A cotton tip applicator is used to apply direct pressure to the needle entry site until no leak of aqueous is confirmed. This procedure can be accomplished when the ligature suture is visible posterior to the tissue patch graft. When placing the tube initially, I leave a little space between the tissue patch graft and the Vicryl ligature to allow for this type of in-office fenestration, if necessary. This technique can temporarily allow aqueous to be released until the tube opens.¹⁻³

In addition to slit-lamp fenestrations, the tube can be opened early before the Vicryl suture dissolves. It is important to place the suture behind the tissue patch graft during the original surgery to allow access to the Vicryl ligature. Argon laser suture lysis of a Vicryl suture can be performed to open the tube prematurely using a 50- μ m spot size, 500 mW, and 500 ms settings (Figure 12-1). I prefer not to open the tube prior to 4 weeks postoperatively to allow the capsule to mature and decrease the risk of hypotony. If forced to open the tube earlier in the setting of a very high pressure in a very advanced glaucoma patient, it is important to have viscoelastic (Healon or Healon GV, Abbott Medical Optics Inc, Abbott Park, Illinois) available to reform the anterior chamber if profound hypotony ensues.

Figure 12-1. Hoskins lens placed over a Vicryl ligature suture to allow good visualization for laser suture lysis. The argon laser can be used to weaken the Vicryl suture and open the tube. The ligation suture was placed posterior to the tissue patch graft to allow access for laser suture lysis.



If the surgeon uses a ripcord suture technique, pulling the ripcord can be a great way to increase the flow of aqueous to the bleb space over the implant if forced to do so by an unacceptable pressure. Again, it is better to wait as long as possible to pull the ripcord suture to allow adequate capsular maturation and lower the risk of hypotony. For very rare cases of unacceptable high IOP before the Vicryl dissolves, the ripcord suture can be removed. This can be done in the office by making a small incision in the conjunctiva overlying the suture with Vannas scissors, and gently removing the suture from the tube lumen with Jeweler's forceps. It is especially useful for those eyes with orbital and lid anatomy that preclude visualization of the posterior tube, making laser suture lysis of the Vicryl ligature suture difficult. See Chapter 8 for more details about the ripcord suture technique.

Management Following Tube Opening

In tubes that are ligated, the type of suture used for ligature will determine when the tube will open. An 8-0 Vicryl suture ligature typically opens at approximately 4 weeks and with a 7-0 Vicryl ligature suture it typically occurs 5 to 7 weeks postoperatively. When the tube opens, the ridge that is seen over the glaucoma drainage implant plate lessens, and a nice bleb is seen over the glaucoma drainage implant plate (Figures 12-2 and 12-3). It is important to see the patient more frequently around the time that the tube is likely to open. I often tell patients this is the second phase of the surgery and much akin to having a "second operation" in terms of frequency of follow-up. It is important to warn patients with ligated, nonvalved implants about the signs and symptoms of tube opening and need for immediate follow-up. Patients should call their surgeon if they notice a change in vision, increased

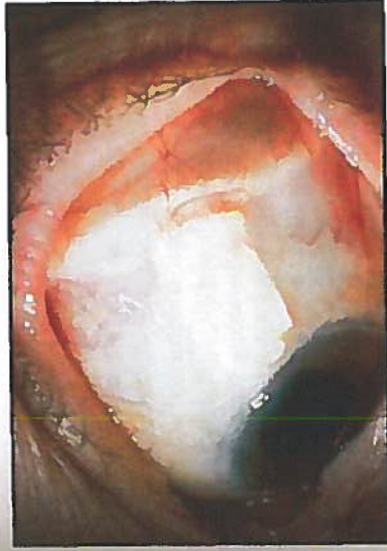


Figure 12-2. Baerveldt glaucoma drainage implant is seen beneath the superior temporal conjunctiva prior to tube opening. The ridge of the glaucoma drainage implant plate is prominent beneath the conjunctiva. (Reprinted with permission from Steve Gedde, MD.)

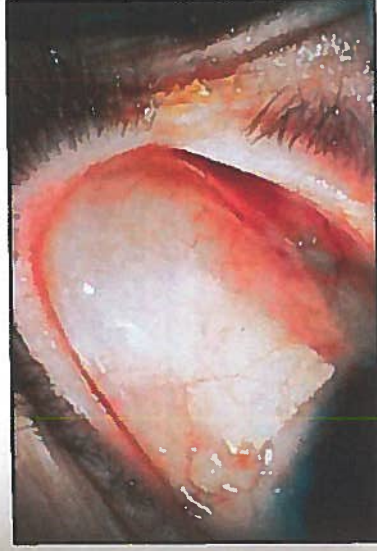


Figure 12-3. Baerveldt glaucoma drainage implant is seen beneath the superior temporal conjunctiva after tube opening. A nice diffuse bleb is seen overlying the glaucoma drainage implant plate. (Reprinted with permission from Steve Gedde, MD.)

redness, or pain. Some surgeons prefer to open the tube in the office at 5 to 6 weeks following tube placement, by lasering the Vicryl ligature or pulling the ripcord suture. It is often necessary to increase the frequency of steroid drops at the time of tube opening due to increased inflammation and sometimes fibrin formation. Some patients may exhibit profound inflammation following the tube opening with significant fibrin formation in the anterior chamber. In these cases, I have found it helpful to use 2 to 4 mg of subconjunctival dexamethasone, which can aid in controlling the inflammation. At times, a longer-acting steroid is needed and sub-Tenon's triamcinolone acetate injection can be very effective.

Rarely, following tube opening, the presence of profound hypotony, with a flat chamber, may require injection of viscoelastic to maintain the chamber. I prefer to use regular Healon for the initial injection and move to a more viscous viscoelastic, such as Healon GV, if the patient fails initially with Healon. It is important to titrate the amount of viscoelastic used

to reform the chamber to avoid a very high pressure. It is better, initially, to use only the amount necessary to deepen the chamber and assess for a response. A viscoelastic overfill can lead to very high pressures, which can require urgent viscoelastic removal. The injection of viscoelastic in the setting of profound hypotony and flat chamber will decrease the risk of a choroidal effusion or hemorrhage, chronic iridocorneal adhesions, or corneal decompensation. This technique should be used with caution in very advanced patients with visual field loss involving fixation, as there is a small risk of very high pressure following viscoelastic injections. It is important to warn patients to call immediately with increased eye pain or brow pain following a viscoelastic injection, which may indicate a high IOP. For management of patients in whom conservative measures fail to address the hypotony, the reader is referred to Chapter 13.

KEY POINTS

1. Valved implants tend to have lower IOP in the early postoperative period.
2. Nonvalved implants, because of ligature and stent sutures, tend to have higher pressures in the immediate postoperative period. Patients and often need to be started back on glaucoma medicines until the tube opens.
3. Fenestrations can provide immediate pressure lowering in a ligated, nonvalved glaucoma drainage implant until the tube has opened.
4. Nonvalved implant patients need to be followed very closely around the time of tube opening because they can exhibit low IOP and increased inflammation.
5. Treat inflammation aggressively to avoid inflammatory complications such as posterior or anterior synechiae, fibrin plug formation causing tube blockage, or pupillary membrane formation.

REFERENCES

1. Triple JR, Brown DB. Occlusive ligature and standardized fenestration of a Baerveldt tube with and without antimetabolites for early postoperative intraocular pressure control. *Ophthalmology*. 1998;105(12):2243-2250.
2. Emerick GT, Gedde SJ, Budenz DL. Tube fenestrations in Baerveldt Glaucoma Implant surgery: 1-year results compared with standard implant surgery. *J Glaucoma*. 2002;11(4):340-346.
3. Kansal S, Moster MR, Kim D, Schmidt CM Jr, Wilson RP, Katz LJ. Effectiveness of nonocclusive ligature and fenestration used in Baerveldt aqueous shunts for early postoperative intraocular pressure control. *J Glaucoma*. 2002;11(1):65-70.

GLAUCOMA DRAINAGE DEVICES MANAGEMENT OF INTRAOPERATIVE AND POSTOPERATIVE COMPLICATIONS

Jonathan A. Eisengart, MD

INTRAOPERATIVE COMPLICATIONS

Tube Transection

Transection of a tube is more common during a revision than during initial insertion. If transection happens at the time of initial insertion, it may be prudent to simply replace the device. However, the techniques described below can be used as well.

If transection occurs during revision or inadvertently during other ocular surgery, it may not be feasible to replace the device. Once transection has occurred, the eye will be very hypotonous, so consider placing viscoelastic into the anterior chamber. The transection itself can be repaired with a commercially available tube extender, the Model TE (New World Medical, Inc. Rancho Cucamonga, California). Although this is easy, the extender is somewhat bulky, needs to be covered with graft material, and may not be immediately available.

An alternative to an extender is to splice in a segment of 22-gauge angiocatheter (Figure 13-1). A short segment can easily slip over each cut end of the transected tube as a sleeve. A 9-0 Prolene suture can then be placed directly through the angiocatheter sleeve and cut tube segment end at each end to secure the sleeve.

Tube Trimmed Too Short

If the tube is placed in the anterior chamber and is 1 to 2 mm too short, the plate can usually be moved forward on the eye. Simply cut 1 or both

Repairing a transected tube with an angiocatheter



Figure 13-1. A 22-gauge angiocatheter placed over the cut tube ends and secured with 9-0 Prolene can be used to lengthen a tube or repair a transection.

plate anchoring sutures, and resecure the plate a little more anteriorly. It is important, however, to make sure the plate is still at least 8 mm or more posterior to the limbus.

If the plate cannot be moved forward enough, then the device can be replaced or the tube can be extended using one of 2 techniques described above.

Scleral Perforation

Scleral perforation is most likely to occur when the plate is being anchored to the sclera, but can occur during any scleral suture pass. Perforation may be recognized by vitreous presenting through the suture tract, pigment egress, and less commonly by hemorrhage or hypotony. Once recognized, the suture should be removed. If the needle may have passed through the retina, then cryotherapy should be applied over and surrounding the needle tract (typically 1 to 3 spots). The temperature is allowed to reach -40 degrees Celsius and remain there for approximately 5 to 10 seconds.

After applying cryotherapy, the surgery is resumed and the plate can be anchored in the same area (it may, in fact, provide a small scleral buckle effect if part of the plate is overlying the perforation). A cycloplegic should be instilled at the end of surgery, and a careful fundus examination performed as soon as possible. A vitreoretinal consultation may be prudent.

Leakage Through Sclerostomy Around the Tube

If there is not a good seal around the tube, then profound hypotony can result. Minimal ooze will typically stop on its own in a few days. If you recognize more than slow ooze around the tube, the tube should be removed, the sclerostomy sutured tight with an 8-0 Vicryl suture, and a new sclerostomy made. Occasionally it may work to tighten the existing sclerostomy with an 8-0 Vicryl suture, but serious hypotony can result if a good seal is not achieved.

POSTOPERATIVE COMPLICATIONS

Although glaucoma tube shunts are subject to some unique complications, many are similar to those found in trabeculectomy. The reader is encouraged to review Chapter 4.

Hypotony

Assessment

Final intraocular pressure (IOP) after tube shunt placement is determined by the rate of aqueous production and the rate of aqueous egress through the tube and capsule. Egress is controlled by the thickness/permeability of the capsule surrounding the plate and the surface area of the plate. Hypotony is caused by an imbalance in which aqueous egress is relatively too high for the level of aqueous production.

In the early postoperative period, overfiltration is the most common cause of hypotony after tube implant surgery. In a valved device, overfiltration is usually due to a failure of the valve mechanism. In a nonvalved tube shunt, very early postoperative overfiltration may be due to inadequate occlusion of the tube, over-zealous fenestration of the tube, or leakage through the sclerostomy around the tube. Overfiltration occurring later than 5 to 6 weeks postoperatively is likely due to lack of adequate encapsulation of the plate.

Aqueous hyosecretion from active iridocyclitis, ischemia, cyclitic membranes, or other forms of ciliary atrophy can also lead to hypotony. Often, a combination of the above factors is at play (eg, an elderly white woman with poor healing and subnormal aqueous secretion develops intractable hypotony after implantation of a large, nonvalved plate).

As is the case after trabeculectomy, the decision of whether to intervene for hypotony must be made based on the present risk to vision. Uncomplicated hypotony can often be observed, whereas a flat anterior chamber needs immediate intervention.

Medical Management

Similar to trabeculectomy overfiltration, tube-shunt overfiltration will often respond to a reduction in steroid dose and, if necessary, cycloplegia. Tapering the steroids will facilitate plate encapsulation, a process that can take several weeks. Having the patient wear a shield at night and avoid eye rubbing can help prevent intermittent tube-corneal endothelial touch. Avoidance of the Valsalva maneuver should be recommended to reduce the risk of choroidal hemorrhage.

If hypotony is not resolving or if the anterior chamber is extremely shallow or flattened, viscoelastic can be injected into the anterior chamber

to temporarily restrict flow through the tube. This can allow some time for the plate to encapsulate. In the setting of ciliary body detachment, which characteristically causes aqueous hyposecretion, the temporary rise in IOP provided the viscoelastic can allow reattachment of the ciliary body and improvement in aqueous secretion. Viscoelastic should be injected through a 27-gauge needle after sterilely prepping the eye and administering a topical antibiotic. Healon is a typical standard choice, and may be retained in the anterior chamber less than 24 hours. Healon GV and Healon 5 allow progressively longer retention and higher achievable IOP.

Surgical Management

If hypotony is not resolving spontaneously or if it is profound, surgical intervention is indicated. The easiest approach is to re-occlude the tube to give the plate more time to encapsulate. This may be done by making a small conjunctival cut-down just anterior to the plate and tightly occluding with a 7-0 Vicryl or 8-0 Prolene suture (the latter option should be wound twice around the tube). Alternatively, the tip of the tube can be delivered from the eye, occluded with an 8-0 Prolene suture wrapped twice, and replaced into the anterior chamber. (The occluding suture will be within the anterior chamber, allowing for easy laser access later.) Prolene sutures can then be "warmed" and loosened at a later date with an argon laser, 500 mW for 500 msec. A red laser may work better than a green laser for Prolene sutures.

If there is recalcitrant or late hypotony, the plate may simply be too large for the eye's ability to produce aqueous and encapsulate the plate. The most assured "cure" of the hypotony is to remove the device (or cut off and remove the tube), although uncontrolled IOP elevation will often result. If the original device was a large, nonvalved plate, it may be replaced with a valved device. A perhaps less successful alternative is to replace it with a smaller version of the same device (eg, changing a Baerveldt 350 mm² to a 250 mm² or a Molteno3) or trimming the existing plate to a smaller size. Silicone or flexible plates can be easily cut to a smaller size with Stevens scissors.

Removing a tube shunt begins by making a conjunctival incision 2 to 3 mm anterior to the plate, parallel to the plate, and at least as wide. The incision is then carried down through Tenon's capsule to sclera and posteriorly to expose the anterior edge of the plate capsule. To help mobilize conjunctiva and eventual wound closure, blunt dissection is then used to separate conjunctiva from underlying capsule. A paracentesis is made so that the anterior chamber can be reformed as needed. The tube is then grasped near the plate (Figure 13-2) and pulled from the anterior chamber. Given the long tract under the conjunctiva and patch graft, there should not be much leakage, but the sclerostomy can be sutured as necessary by making a small peritomy at the limbus to elevate the patch graft. The capsule

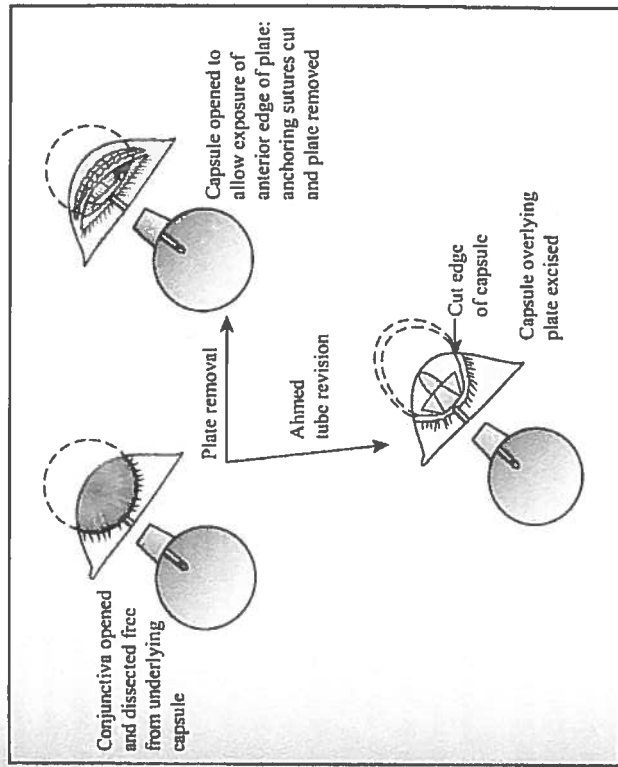


Figure 13-2. Accessing the plate for removal or revision.

surrounding the plate should then be sharply entered near the anterior edge of the plate and the incision extended widely to expose the entire anterior edge of the plate. Next, cut the sutures anchoring the plate to the sclera. To find and cut the fibrous "stalks" that have grown through a Baerveldt's plate fenestrations, place blunt-tipped scissors on top of the plate and "strum" the stalks to locate them. Most plates can now be easily pulled out, although large Baerveldt plates may be more easily removed if one wing is cut off first. If necessary, a smaller tube shunt can then be placed in the existing Tenon's "pocket" or placed in a new quadrant.

Hypertensive Phase

Any type of glaucoma drainage device can go through a hypertensive phase, but it is more common, or at least more easily noticed, in valved devices that are not tied off initially. The hypertensive phase is typically seen at 4 to 5 weeks² postoperatively, when the IOP begins to rise. Often, a moderate to high encapsulated bleb is noted.

First-line treatment is to taper steroids if possible, because steroid-responsive IOP rise is definitely possible despite a functioning tube. Early use of aqueous suppressants can also be helpful, not only to lower the IOP

but also to potentially "soften" the capsule by lessening internal pressure and stretching of the capsule. Typically, I will avoid early use of outflow agents (ie, prostaglandin analogs) because they can be somewhat inflammatory in the early postoperative period and because there is already some functional outflow from the tube shunt.

Tube Exposure

Assessment

Erosion of the tissues overlying the tube usually occurs months to years after tube placement, although occasionally it can occur earlier. It is typically seen approximately 2 to 4 mm posterior to the limbus, presumably due to pressure and rubbing from the upper lid tarsus. Tube exposure needs to be repaired because it can lead to endophthalmitis and even orbital cellulitis. Although a patient may be temporized with topical antibiotics, management of tube exposures is purely surgical.

If signs of infection are seen, such as anterior chamber reaction or purulence, intense antibiotic treatment should be instituted and consideration given to tube removal. Clearly, any hint of endophthalmitis should be referred to a vitreoretinal specialist.

Surgical Management

In my experience, most cases of tube exposure have occurred in tubes originally covered by pericardium. If that is the case, I will try once to re-cover the tube with donor sclera or rarely split-thickness cornea, both of which are more durable in the eye than pericardium (if the tube erodes through sclera, I will often reposition the tube as described below). I typically make my incision at the limbus, anterior to the plate, or along the area of erosion depending on the location and amount of scarring. Careful, gentle dissection is then used to elevate conjunctiva off the tube and surrounding sclera to make a pocket large enough to accommodate a new graft. The new graft material is slipped into place and sutured with 8-0 Vicryl. Often, there is extensive scarring, and mobilizing adequate conjunctiva is difficult. Additionally, the original erosion leaves a hole in the conjunctiva that may overlie the new patch graft. Exposed scleral patch grafts will typically epithelialize and then vascularize in a few weeks. If a large area of patch graft remains exposed at the end of the surgery, amniotic membrane or a free conjunctival graft can be sutured to fill in the conjunctival defect.

If the tube erosion is recurrent or there is not enough mobile conjunctiva to allow re-covering of the tube, then the tube needs to be repositioned to change the way it interacts with the eyelid. One option is to

remove the device (or just cut off and remove the tube) and place a new device in another quadrant. However, I have had excellent success by repositioning the tube into the pars plana. If the patient has not already had a complete pars plana vitrectomy with trimming of the vitreous skirt, I will perform the surgery in conjunction with one of my vitreoretinal colleagues. Once the vitreous has been cleared, I begin repositioning the tube by making a 2 to 3 clock-hour limbal peritomy with short radial relaxing incisions in the quadrant with the tube. Conjunctiva is elevated, the tube tip is removed from the eye, and the sclerostomy is sutured with 8-0 Vicryl. The tube is then placed into the pars plana through a fresh 23-gauge needle tract. For further details on pars plana placement of the tube, please see Chapter 38.

Plate Erosion

Late erosion of the plate is uncommon but cannot be repaired. Direct suturing of the conjunctiva or covering the plate with graft material almost always fails. In these cases, the exposed device should be removed. If necessary, another tube can be placed in a different quadrant, or ciliary body ablation can be performed.

Early postoperative wound dehiscence can be successfully resutured if there is healthy conjunctiva and minimal wound tension. Friable conjunctiva or excessive wound tension should be approached by replacing the device into another quadrant.

Tube Occlusion

Occlusion in the Anterior Chamber

Tube occlusion can occur at the tip of the tube in the anterior chamber. Occlusion is easily recognized in the anterior chamber if iris, fibrin/blood clot, silicone oil, or other substance is seen at the end of the tube in association with an elevated IOP.

Frequently, these occlusions may be cleared with the YAG laser. Rarely, pilocarpine helps pull iris out of the tube, but the iris may come back up into the tube at a later date. Fibrin or blood clot may be treated with tissue plasminogen activator (tPA), 3 to 25 μ g injected into the anterior chamber through a 30-gauge needle. (An inpatient hospital pharmacy or compounding pharmacy can dilute the intravenous tPA solution to 100 to 250 microgram/mL, and 0.1 cc is injected at the slit lamp.³) Of course, intracameral tPA can lead to a total hypohema if fresh wounds or fragile vessels remain.

Occlusion of the Valve Mechanism

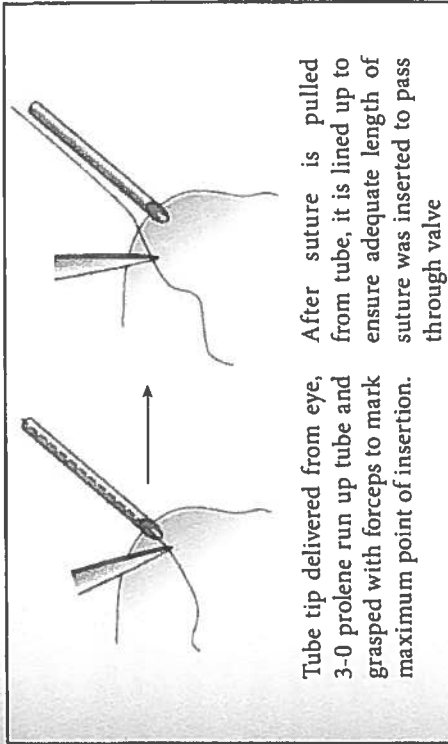
A valved device, in particular Ahmed tubes, can also become obstructed at the level of the valve mechanism. Obstruction can be due to material lodged in the valve mechanism or from fibrous bands growing retrograde from the plate up the tube. Valve obstruction is often difficult to differentiate from simple plate encapsulation. However, when the IOP is elevated, careful inspection of the bleb can be revealing. When the valve is obstructed, the bleb will be absent, the conjunctiva will be closely adherent to the plate, and detailed structures of the plate will frequently be visible through the conjunctiva. With plate encapsulation, the bleb may be low but not flat, and detailed structures of the plate are not visible. B-scan ultrasonography also may be helpful to look for fluid surrounding the plate.

If valve obstruction is confirmed, firm ocular massage may force aqueous through the valve and occasionally relieve the obstruction. This technique tends to work best in the first few days after surgery.

If massage fails, the tube may be considered to have failed. Options for managing tube failure are discussed below in the section on cyclodestruction.

However, I have had success in surgically clearing a valve obstruction with a planned 2-step approach. In the operating room, begin by getting a careful baseline examination of the flat bleb because you will be looking for it to elevate when the obstruction is relieved. The first attempt to clear the obstruction is made by passing a 3-0 Prolene suture up the tube through the valve. The Prolene can be placed into the tube by delivering the tip of the tube from the eye, or by making a paracentesis 180 degrees away from the tube and running the tube across the anterior chamber. As the suture is advanced, you may feel resistance and then a "give" as the suture passes through the valve. Once the suture is inserted as far as it can go, it is important to ensure it has passed the valve (Figure 13-3), especially if it cannot be directly seen through the conjunctiva. With tying forceps, grasp the Prolene right at the tip of the tube (or at the paracentesis if the suture was passed through the cornea) and *without letting go*, pull the Prolene out. Your forceps now mark the maximum point where the suture was inserted, so you can lay the Prolene on the eye, lining up your forceps with the tube tip/paracentesis, to make sure adequate suture length was inserted to pass through the valve. Next, deepen the anterior chamber and raise the IOP substantially. Check to make sure that the bleb forms and that the IOP comes down over several minutes. Many times this maneuver will be successful.

If there is still no evidence of tube function, the obstruction is more likely due to fibrous growth into the valve or tight encapsulation overlying the valve outlet. I have found success in these situations by cutting away the capsule overlying the plate (only in valved devices, otherwise profound hypotony will



Tube tip delivered from eye, After suture is pulled 3-0 Prolene run up tube and from tube, it is lined up to grasped with forceps to mark ensure adequate length of maximum point of insertion. suture was inserted to pass through valve

Figure 13-3. Passing suture up Ahmed tube and ensuring adequate length was inserted to clear valve.

result). Begin by making a conjunctival incision 2 to 3 mm anterior to, and parallel to, the plate and at least as wide as the plate. Carry it deep to the sclera, taking care to avoid cutting the tube. Identify the anterior edge of plate, and bluntly and broadly dissect conjunctiva and Tenon's off of the capsule surrounding the plate. Next, sharply enter the capsule at the anterior edge of the plate and excise as much capsule tissue as possible. Often, as the thick encapsulation is pulled up off the plate, a fibrous extension can be seen extending into the valve. Once the valve is cleared, aqueous should flow immediately (if it does not, the plate should be replaced or the valve mechanism disassembled). Close the conjunctiva-Tenon's complex with a running 8-0 Vicryl suture. To prevent the incision from overlying the plate where it can leak, take anterior anchoring bites of Tenon's, scar, and/or sclera as the suture is run.

Tube Failure

For the purpose of this discussion, tube failure is considered to occur when the IOP remains too high despite a bleb over the plate and maximum tolerated hypotensive therapy.

This situation can be difficult to manage, and there are essentially 3 options: revision of the existing tube, placement of a second tube, or cyclodestruction.

Revision of the Existing Tube

This involves cutting away the thick capsule overlying the plate as described above. This can be successful in some cases, but the capsule may

reform. In a valved device, this technique has the advantage of relatively rapid patient recovery and low operative risk. I will often try a revision of an Ahmed tube before placing a second device.

If a nonvalved device is revised, then it must be temporarily reoccluded to prevent profound hypotony. For that reason, I do not attempt to revise nonvalved devices.

Placement of a Second Tube Shunt

A second tube shunt is often quite successful, as long as there is an available quadrant to place it in. In most cases, I will implant a Baerveldt 250 mm² or 350 mm² as a second tube because it is low profile and highly effective. An Ahmed may be a reasonable second choice, but its higher profile can lead to proptosis or inferior globe displacement when another drainage device is already in place. However, if the first implant provided very minimal benefit, then a second device may not work much better.

Cyclodestruction

Transscleral or endoscopic cyclophotocoagulation can be highly effective in the setting of some functional outflow (eg, the tube shunt). Treatment parameters are the same as for an eye without a tube shunt in place. For a transscleral approach, however, I will typically avoid treating the quadrant with the tube shunt because the graft and tube itself will make treatment of the underlying ciliary body less predictable. Cyclodestruction may be a less desirable in phakic patients, however, due to the rapid formation of advanced cataract.

Corneal Edema and Decompensation

The presence of any foreign object within the anterior chamber can lead to progressive loss of corneal endothelial cells and eventual corneal edema. The rate of endothelial cell loss has been reported at 18.6% at 24 months and even higher in the quadrant with the tube.⁴

Prevention

Progressive corneal endothelial cell loss is thought to be due to intermittent tube–corneal touch. A long tube or an anteriorly directed tube are risk factors for progressive corneal edema. Additionally, corneal endothelial cells may be lost at the site of the sclerostomy. Ideally, the sclerostomy should be made so that the tube enters *posterior* to Schwalbe's line, which will ensure no portion of the tube is in contact with the corneal endothelium.

Surgical Management

If a tube is too long, the tip can be delivered from the anterior segment and trimmed. Alternatively, it can be trimmed directly within the anterior

chamber.⁵ If the tube is anteriorly directed, the tip should be removed, the sclerostomy sutured closed, and the tube reinserted in an appropriate direction.

When corneal edema related to a tube is noted, the tube should ideally be removed or repositioned into the posterior segment (please see Chapter 38). If visually significant corneal edema has already developed, a corneal endothelial graft or penetrating keratoplasty may be required. The success of a corneal graft in this situation may be improved if the tube is removed or repositioned posteriorly.

KEY POINTS

1. A piece of 22-gauge angiocatheter can be spliced in to extend or repair a tube.
2. Leakage around the tube can result in intractable hypotony, and anything more than a minimal ooze needs to be addressed before leaving the operating room.
3. Early postoperative hypotony is likely due to failure of the valve mechanism in valved devices, poor occlusion or over-fenestration in nonvalved devices, or leakage around the tube in either type of device.
4. Late postoperative hypotony is due to poor encapsulation of the plate and/or reduced aqueous production.
5. A "hypertensive" phase is common, but typically IOP can be controlled by tapering steroids and adding ocular hypotensive medications.
6. When the IOP is too high after implantation of a valved device, look for a flat bleb to rule out valve obstruction.
7. Failed drainage devices can be addressed by revision (for valved devices), placing a second device, or cyclodestruction.

REFERENCES

1. García-Feijóo J, Cuiña-Sardiña R, Méndez-Fernández C, Castillo-Gómez A, García-Sánchez J. Pertubular filtration as a cause of severe hypotony after Ahmed valve implantation for glaucoma. *Am J Ophthalmol*. 2001;132(4):571-572.
2. Nouri-Mahdavi K, Caprioli J. Evaluation of the hypertensive phase after insertion of the Ahmed Glaucoma Valve. *Am J Ophthalmol*. 2003;136(6):1001-1008.
3. Zalta AH, Sweeney CP, Zalta AK, Kaufman AH. Intracameral tissue plasminogen activator use in a large series of eyes with valved glaucoma drainage implants. *Arch Ophthalmol*. 2002;120(11):1487-1493.
4. Lee EK, Yun YJ, Lee JE, Yim JH, Kim CS. Changes in corneal endothelial cells after Ahmed glaucoma valve implantation: 2-year follow-up. *Am J Ophthalmol*. 2009;148(3):361-367.
5. Asrani S, Herndon L, Allingham RR. A newer technique for glaucoma tube trimming. *Arch Ophthalmol*. 2003;121(9):1324-1326.

EX-PRESS GLAUCOMA FILTRATION DEVICE

Mahmoud A. Khairi, MD and Malik Y. Kahook, MD

Since its inception in the 1960s, the gold standard for surgical treatment of glaucoma has been the trabeculectomy.¹ The goal of this glaucoma filtering surgery is to create an alternative route for aqueous humor to drain out of the eye and into a subconjunctival reservoir, thus creating a bleb. More recently, incremental advancements in microsurgical device manufacturing has paved the way for the introduction of the Ex-Press glaucoma filtration device as a valuable adjunct to trabeculectomy.

OVERVIEW AND SURGICAL TECHNIQUE

The Ex-Press glaucoma filtration device is a nonvalved, MRI-compatible, stainless steel device that is inserted under a scleral flap into the anterior chamber to shunt aqueous to a subconjunctival reservoir.² The device is approximately 3 mm in length and has a 400- μ m external lumen. Currently, the R and P models are available, with the P model being the most widely used. The P model is available with 50- or 200- μ m internal lumens (Figure 39-1). The devices are preloaded on an injector device to minimize intraoperative device manipulation and for simplification of delivery (Figure 39-2).

The surgical technique for a trabeculectomy using the Ex-Press device is very similar to the standard trabeculectomy procedure. However, there are key differences that will be noted. The anesthetic used for this procedure should not vary from what the surgeon is originally accustomed to with traditional trabeculectomy. We prefer a retrobulbar block containing a half-and-half mixture of 0.4% lidocaine, 0.75% marcaine, and added Wydate for a total of 5 cc. The patient is prepped and draped in the same fashion and a standard fornix or limbal-based conjunctival flap is then created to

P-So
MOST
COMMON

CONNER

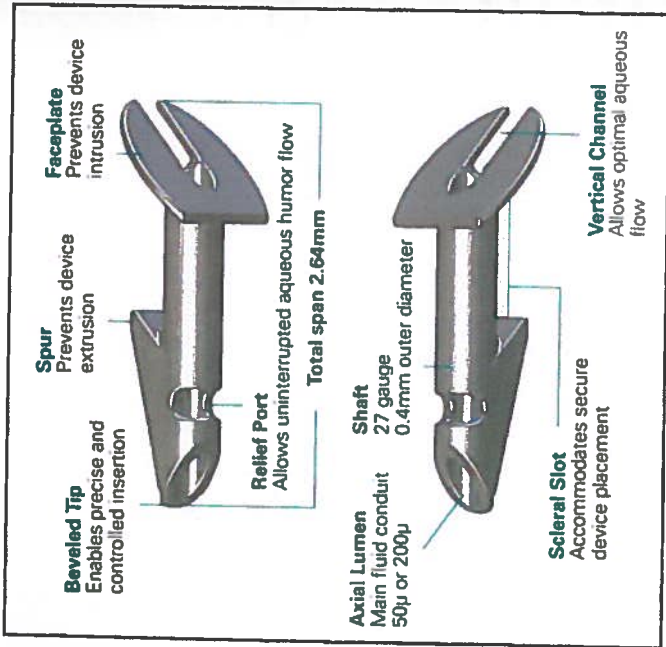


Figure 39-1. Ex-Press device, P-model.

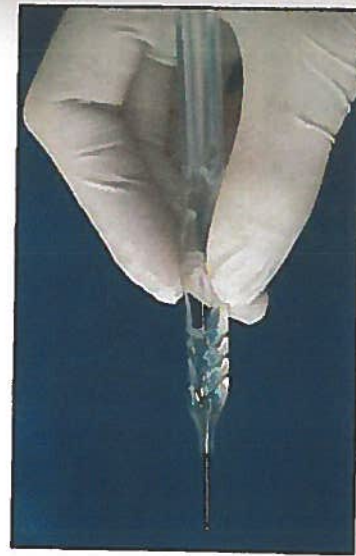

Figure 39-2. Ex-Press injector device.

provide access to the scleral bed at the limbus. Wet-field cautery is used for homeostasis and a scleral flap is then created with the surgeon's blade of choice. The scleral flap should extend into clear cornea. **Note:** Close attention should be paid to the following: (1) fashion a scleral flap that is a least half-thickness wide and, at minimum, 3- to 3.5-mm wide and long;

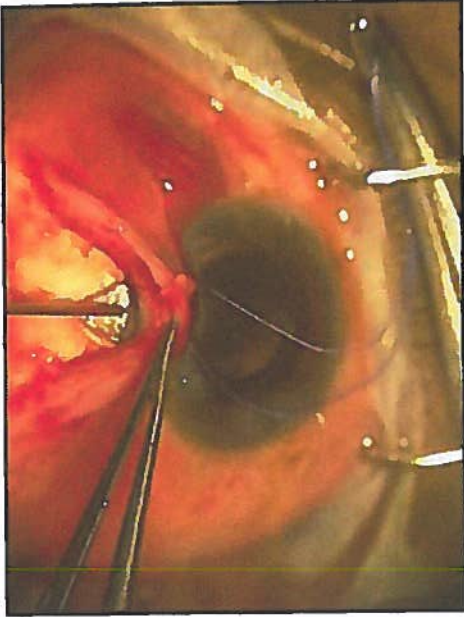


Figure 39-3. Creation of scleral ostia with a 25-gauge needle.

and (2) create a uniplanar flap dissection. Both of these critical points will ensure adequate coverage of the device face plate to avoid overfiltration and conjunctival extrusion.³⁻¹³ As with traditional trabeculectomy, the shape of the flap (triangular, pentagonal, rectangular) does not seem to affect the outcome. Antifibrotics are then used in the usual manner for trabeculectomy. In anticipation of device placement, a clear corneal paracentesis is then created to provide access for reformation of the anterior chamber and assessment of aqueous egress.

The prefashioned scleral flap is then lifted and the "blue line" (trabecular meshwork) adjacent to clear cornea should be identified. Next, a 25-gauge needle (a 26- or 27-gauge needle may also be used) is then used to enter the anterior chamber just posterior to the blue line (Figure 39-3). The needle should be directed parallel to the iris plane, and the tip of the needle should fully enter the anterior chamber. Care should be taken to avoid needle-to-iris or -lens contact to minimize complications. However, the needle must completely enter the eye to create a patent scleral ostia for proper insertion of the implant. The Ex-Press, which is preloaded on an injector, is then threaded into the eye through the ostium (Figure 39-4) created in the previous step. **Note:** Close attention should be paid to entering the anterior chamber at the same angle used with the needle. Failure to do so may result in difficulty in inserting the implant, which may potentially widen the ostia and subsequently lead to overfiltration and loose fixation of the device to the sclera. The surgeon should also become familiarized with the injector device and specifically the central ridge,

25g
trabecular

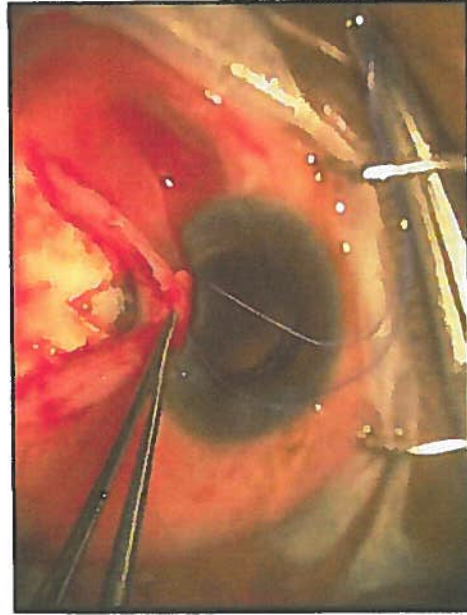


Figure 39-4. Scleral ostia.

where one must press to release the device prior to inserting it. Placement of the surgeon's finger anterior or posterior to the central ridge will result in greater effort required to release the device. Knowing the intricacies of the preloaded injector will help to promote a safer and uncomplicated insertion of the device. After the device is inserted, care is taken to make sure that it is well placed into the anterior chamber away from the corneal endothelium and iris and well situated on the scleral bed (face plate flush with the sclera). Furthermore, for the P version implants, the posterior groove on the footplate should point posteriorly toward the apex of the flap to promote posterior flow of aqueous.

As with traditional trabeculectomy, the scleral flap is then reapproximated to sclera with 10-0 nylon sutures. Two to 5 interrupted sutures are typically placed through the scleral flap. Flow can be assessed by injecting balanced salt solution through the previously created corneal paracentesis. After the amount of fluid flow is deemed appropriate and the eye pressure is adequate, the conjunctiva is closed with the surgeon's suture and technique of choice (ie, single versus double, running versus interrupted).

Our postoperative care is similar to our standard post-trabeculectomy regimen of topical steroids and antibiotics. Furthermore, postsurgical modifications, such as laser suture lysis, are similar to standard trabeculectomy parameters. Anecdotally, however, we have found that with the utilization of the Ex-Press device, earlier and more aggressive suture lysis is possible without an increased rate of hypotony.

CONCLUSION

The Ex-Press glaucoma filtration device has been a promising adjunct to the traditional glaucoma filtering procedure. Kanner et al¹⁴ in a large case series, along with other studies,^{15,16} have shown that use of the Ex-Press device under a scleral flap had similar intraocular pressure (IOP)-lowering efficacy compared with trabeculectomy. Thus, over the past half decade, placement of the Ex-Press device has exponentially increased. The Ex-Press has gained vast popularity worldwide for its ease of usage and for the advantages it offers both the patient and surgeon intra- and postoperatively over traditional trabeculectomy. One major difference between the traditional trabeculectomy and Ex-Press implantation is there is less intraocular manipulation of tissue when using the Ex-Press device. Unlike traditional trabeculectomy, a surgical iridectomy is not performed when using an Ex-Press device. This avoids the complication that can potentially arise when performing a surgical iridectomy (ie, hyphema and inflammation) and has led to less of an inflammatory response in the immediate postoperative period.^{15,17,18} Furthermore, because the scleral ostia is much smaller than a typical sclerotomy created by a Kelley punch, intraoperatively, the eye tends to be much more stable with less incidence of hypotony leading to shallow or flat chambers.^{14,16} Less intraocular instability and complications have led many to believe that the postoperative visual recovery is faster in patients in whom an Ex-Press filtering procedure has been performed. In fact, a recent study conducted by Good and Kahook¹⁶ has shown that patients who received an Ex-Press device had quicker visual recovery, fewer postoperative visits, and experienced fewer episodes of postoperative hypotony and hyphema compared with patients who had traditional trabeculectomy. The Ex-Press glaucoma filtration device procedure has thus emerged as a safe and effective alternative to the traditional trabeculectomy procedure.

REFERENCES

1. Cairns JE. Trabeculectomy: preliminary report of a new method. *Am J Ophthalmol.* 1968;66(4):673-679.
2. Seibold LK, Rorrer RA, Kahook MY. MRI of the Ex-Press stainless steel glaucoma drainage device. *Br J Ophthalmol.* 2011;95(2):251-254.
3. Kaplan Messas A, Traverso CE, Sellem E, Zagorsky ZF, Belkin M. The Ex-Press miniature glaucoma implant in combined surgery with cataract extraction: prospective study. *Invest Ophthalmol Vis Sci.* 2002;43:E-abstract 3348.
4. Gandolfi S, Traverso CF, Bron A, et al. Short-term results of a miniature drainage implant for glaucoma in combined surgery with phacoemulsification. *Acta Ophthalmol Scand Suppl.* 2002;236:66.
5. Traverso CE, De Feo F, Messas-Kaplan A, et al. Long term effect on IOP of a stainless steel glaucoma drainage implant (Ex-Press) in combined surgery with phacoemulsification. *Br J Ophthalmol.* 2005;89:425-429.

6. Wamsley S, Moster MR, Rai S, et al. Results of the use of the Ex-Press miniature glaucoma implant in technically challenging, advanced glaucoma cases: a clinical pilot study. *Am J Ophthalmol.* 2004;138:1049-1051.
7. Wamsley S, Moster MR, Rai S, et al. Optonol Ex-Press miniature tube shunt in advanced glaucoma. *Invest Ophthalmol Vis Sci.* 2004;45:E-abstract 994.
8. Stewart RM, Diamond JG, Ashmore ED, et al. Complications following Ex-Press glaucoma shunt implantation. *Am J Ophthalmol.* 2005;140:340-341.
9. Rivier D, Roy S, Mermoud A. Ex-Press R-50 miniature glaucoma implant insertion under the conjunctiva combined with cataract extraction. *J Cataract Refract Surg.* 2007;33:1946-1952.
10. Tavolato M, Babighian S, Galan A. Spontaneous extrusion of a stainless steel glaucoma drainage implant (Ex-Press). *Eur J Ophthalmol.* 2006;16:753-755.
11. Garg SJ, Kanitkar K, Weichel E, et al. Trauma-induced extrusion of an Ex-Press glaucoma shunt presenting as an intraocular foreign body. *Arch Ophthalmol.* 2005;123:1270-1272.
12. Filippopoulos T, Rhee DJ. Novel surgical procedures in glaucoma: advances in penetrating glaucoma surgery. *Curr Opin Ophthalmol.* 2008;19:149-154.
13. Stein JD, Herndon LW, Bond JB, Challa P. Exposure of Ex-Press miniature glaucoma devices: case series and technique for tube shunt removal. *J Glaucoma.* 2007;16:704-706.
14. Kanner E, Netland PA, Sarkisian SR, Du H. Ex-Press miniature glaucoma device implanted under a scleral flap alone or in combination with phacoemulsification cataract surgery. *J Glaucoma.* 2009;18(6):488-491.
15. Maris PJ Jr, Ishida K, Netland PA. Comparison of trabeculectomy with Ex-Press miniature glaucoma device implanted under scleral flap. *J Glaucoma.* 2007;16:14-19.
16. Good TJ, Kahook MY. Assessment of bleb morphologic features and postoperative outcomes after Ex-Press drainage device implantation versus trabeculectomy. *Am J Ophthalmol.* 2011;151(3):507-513.
17. Nyska A, Glovinsky Y, Belkin M, et al. Biocompatibility of the Ex-Press miniature glaucoma drainage implant. *J Glaucoma.* 2003;12:275-280.
18. Mermoud A. Ex-Press implant. *Br J Ophthalmol.* 2005;89:396-397.

CANALOPLASTY

Mahmoud A. Khairi, MD

Traditionally, the gold standard for surgical treatment of open-angle glaucoma (OAG) has been trabeculectomy with the use of antifibrotic therapy. The goal of the trabeculectomy procedure is to create an alternative route for aqueous humor to drain out of the eye and into a subconjunctival reservoir, thus creating a bleb. Despite the fact that the trabeculectomy surgery has proven to be effective in both lowering intraocular pressure (IOP) and halting the progression of the disease process, it is not without the risk of immediate or delayed postsurgical complications.¹⁻⁶ Therefore, there has been a growing interest amongst surgeons to seek out and develop IOP-lowering procedures that do not rely on the creation of a bleb and avoid the utilization of antifibrotics. One such procedure that has successfully fulfilled these requirements is canaloplasty with circumferential dilation and suture tensioning of Schlemm's canal. Canaloplasty has gained increasing popularity as a surgical procedure that promotes the rejuvenation of the natural conventional outflow pathway without the formation of a bleb. Studies have shown that canaloplasty has proven to be similar to trabeculectomy in effectively lowering IOP and appears to have a safer postoperative profile.⁷⁻⁸

SURGICAL PROCEDURE

Canaloplasty is accomplished by exposing Schlemm's canal via non-penetrating dissection and using the iTrack 250 flexible microcatheter (Figure 40-1) to circumferentially viscodilate and intubate Schlemm's canal with a tensioning suture. Furthermore, the microcatheter is also unique in that it has a beacon tip to allow for transscleral illumination during catheterization.

Typically, anesthesia and akinesia are achieved with a retrobulbar block. A corneal traction suture is placed superiorly next to the limbus. Next, a fornix-based conjunctival incision is created, followed by careful dissection